

# Photoacoustic breast imaging in the HYMPACT project

Michelle Heijblom<sup>1,2</sup>, Wenfeng Xia<sup>1</sup>, Daniele Piras<sup>1</sup>, Johan van Hespem<sup>1</sup>, Joost Klaase<sup>2</sup>, Frank van den Engh<sup>2</sup>, Arjen Amelink<sup>3</sup>, Ute Gamm<sup>3</sup>, Dick Sterenberg<sup>3</sup>, Ton van Leeuwen<sup>1</sup>, Wiendelt Steenbergen<sup>1</sup> and Srirang Manohar<sup>1</sup>

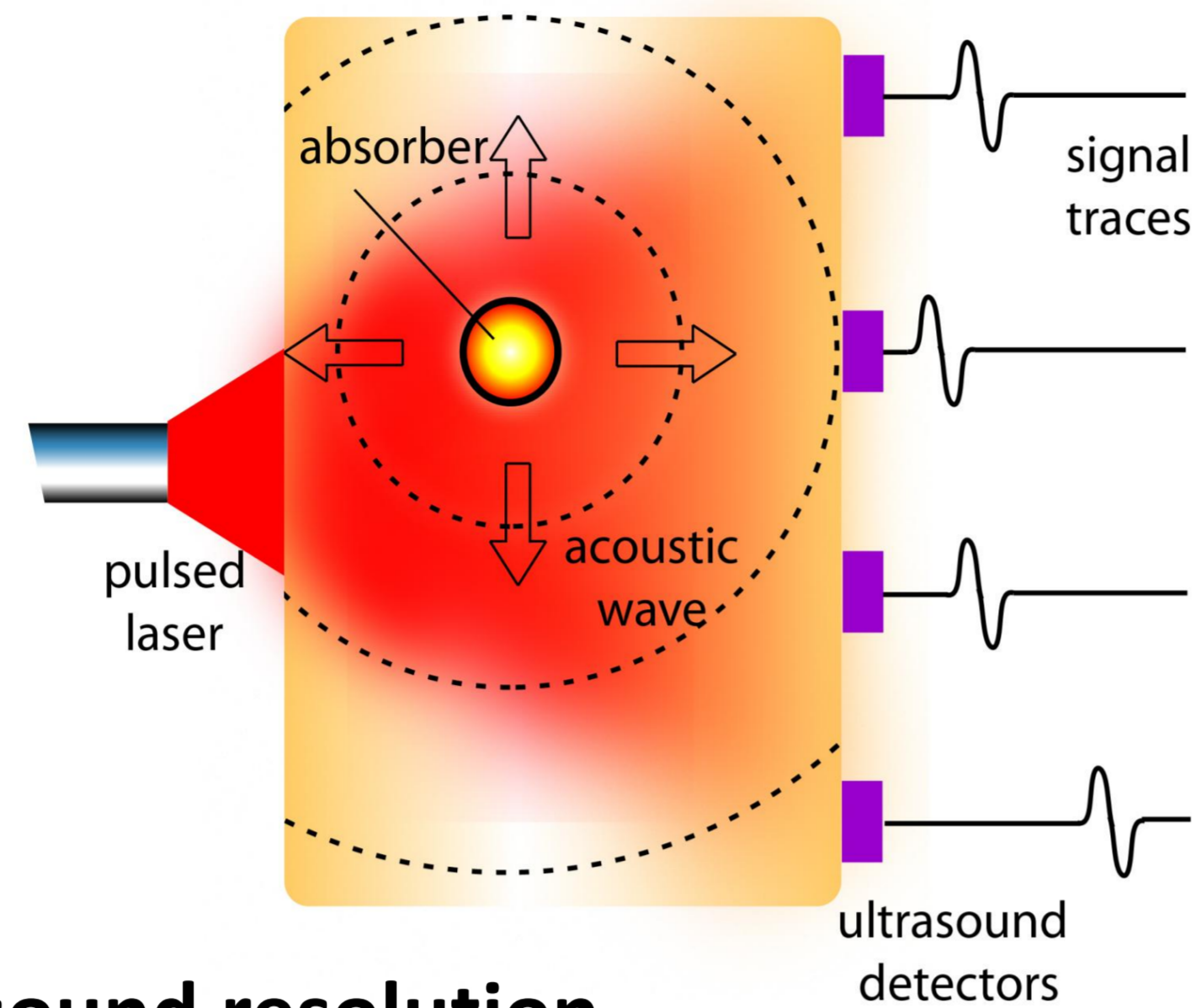
<sup>1</sup> Biomedical Photonic Imaging (BMPI), University of Twente, Enschede, the Netherlands

<sup>2</sup> Centre for Mammacare, Medisch Spectrum Twente, Enschede, the Netherlands

<sup>3</sup> Erasmus Medical Center, Rotterdam, the Netherlands

## Photoacoustic Mammography

1. Malignancy:
  - ↑ blood vessels, ↑ Hb.
2. Pulsed laser light;
3. Absorption by Hb;
4. Temperature ↑;
5. Thermo-elastic expansion;
6. US wave, US detection.



→ Optical contrast and ultrasound resolution

## Twente Photoacoustic Mammoscope (PAM I)



Manohar et al. Optics Express 2007

## Study details

- Study location: Medisch Spectrum Twente, Oldenzaal;
- Study duration: 1.5 year;
- Start study: November 2010;
- No. of patients: 50-100.

## Data handling

- Off-line image reconstruction:
  - delay and sum vs backprojection;
- Comparison to conventional imaging;
- Comparison to histopathology.

## Partners



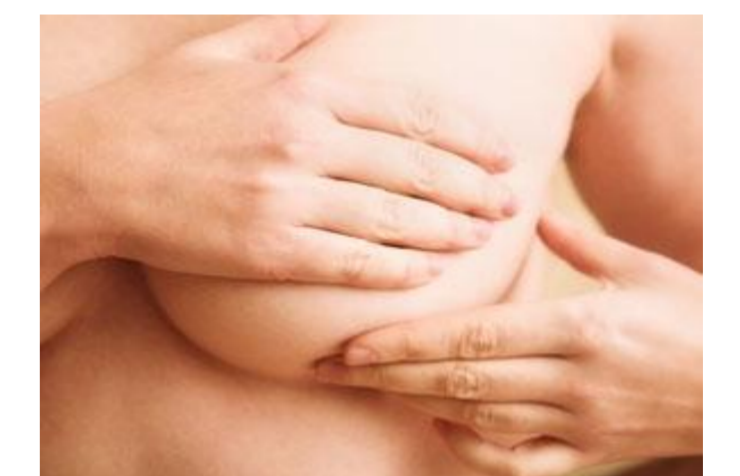## Acknowledgements



## Centre for Mammacare:

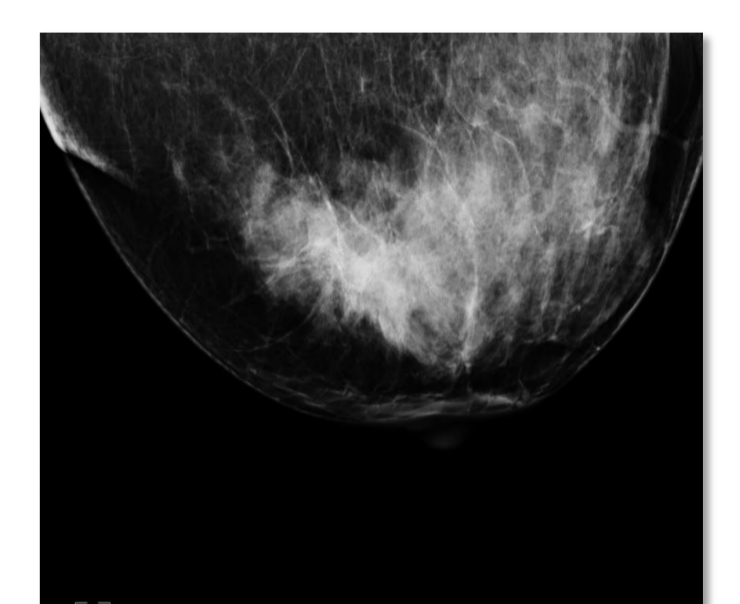- Nurse practitioner:
  - Clinical investigation;
  - Anamnesis.

800 patients/year

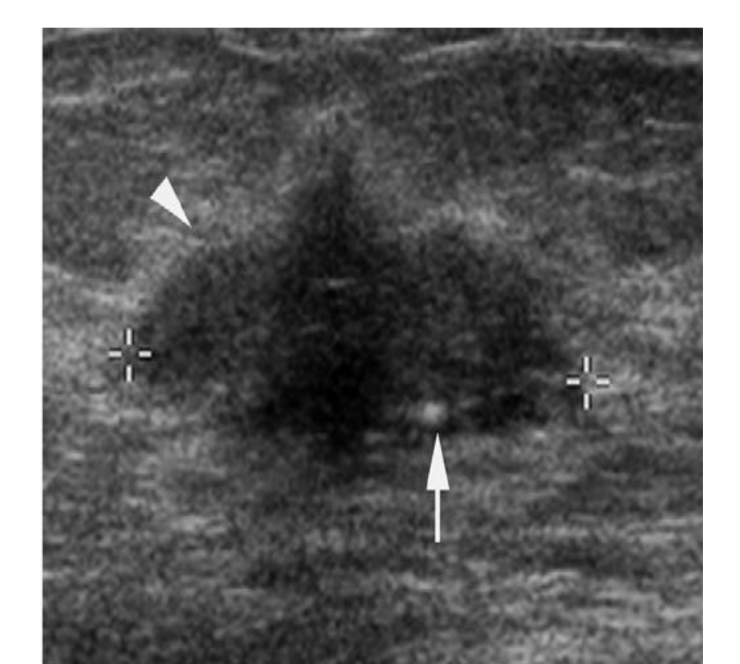


- Radiology:
  - X-ray mammography;
  - Ultrasonography.

800 patients/year

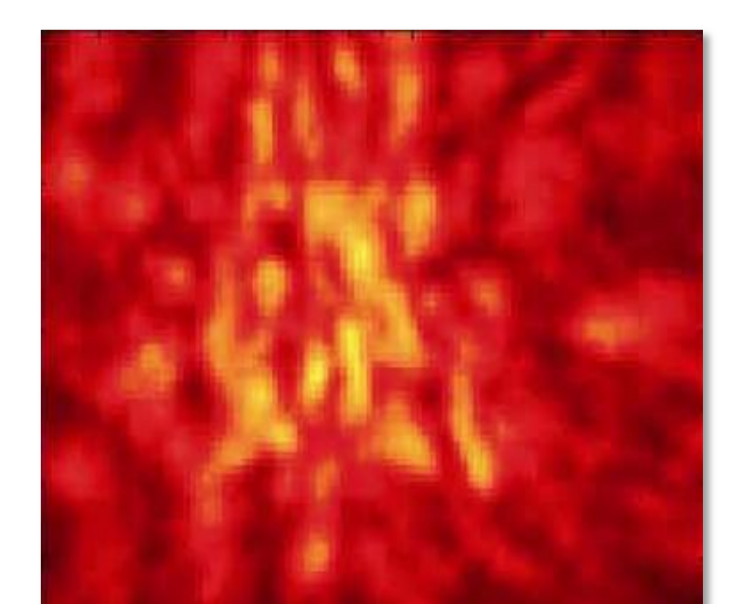


BIRADS 5	BIRADS 4	BIRADS 3	BIRADS 2	BIRADS 1
Almost certain malignancy.	Suspicious for malignancy.	Probably benign lesion.	Benign lesion.	Normal breast tissue.



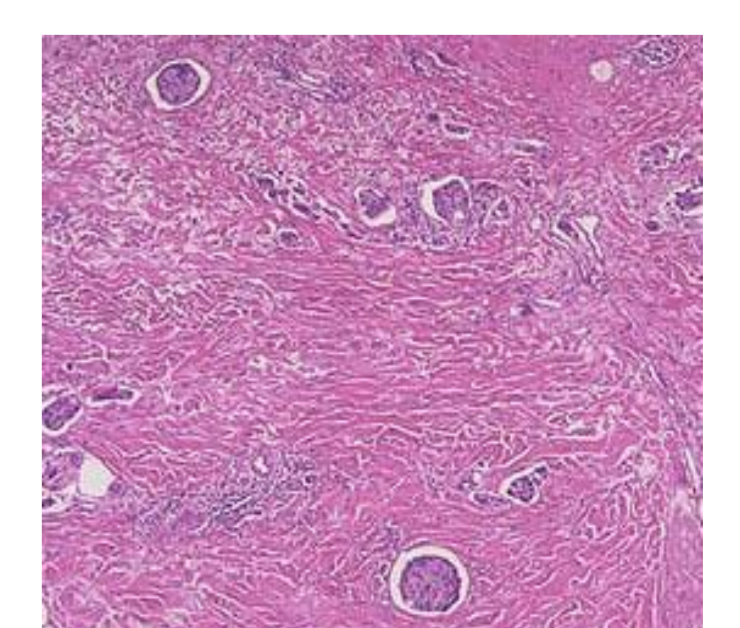
- Photoacoustic imaging study:
  - Phase 1 & 2:**
  - Nr. of subjects: 60 (BIRADS 4,5);
  - Months: 1-16;
  - Goals:
    - Improve measurement methods;
    - Find photoacoustic malignancy markers.

- Photoacoustic imaging study:
  - Phase 3:**
  - Nr. of subjects: 20 (BIRADS 1,2);
  - Months: 14-18;
  - Goal:
    - Evaluate absence of malignancy markers.



- US guided biopsy; 400 patients/year
- (& differential pathlength spectroscopy).

- Make appointments for additional investigations/follow up;
- Send patient home.



- Multidisciplinary meeting.

- Give patient preliminary diagnosis.