

1  
2  
3  
4  
5  
6  
7  
8  
9  
10  
11  
12  
13  
14  
15  
16  
17  
18  
19  
20  
21  
22  
23  
24  
25  
26  
27  
28  
29

Review article

Imaging breast tumor vascularization for detection and diagnosis of breast cancer

<sup>1,2</sup> M. Heijblom, MSc

<sup>2</sup> J.M. Klaase, MD, PhD

<sup>2</sup> F.M. van den Engh, MD

<sup>1,3</sup> Prof. T.G. van Leeuwen

<sup>1</sup> Prof. W. Steenbergen

<sup>1</sup> S. Manohar\*, PhD

<sup>1</sup>Biomedical Photonic Imaging Group, MIRA Institute for Biomedical Technology and Technical Medicine, University of Twente, P.O. Box 217, 7500 AE Enschede, the Netherlands

<sup>2</sup>Center for Breast Care, Medisch Spectrum Twente hospital, P.O. Box 50000, 7500 KA, Enschede, the Netherlands

<sup>3</sup>Biomedical Engineering and Physics, Academic Medical Center, University of Amsterdam, P.O. Box 2270, 1100 DE Amsterdam, the Netherlands

**\*Corresponding author:**

S. Manohar, PhD

Tel: +31 534893164

[s.manohar@utwente.nl](mailto:s.manohar@utwente.nl)

**Short running title:** Imaging breast tumor vascularization

**Key words:** Breast cancer, imaging, vasculature, angiogenesis, MRI, mammography, ultrasonography, optical imaging, photoacoustic imaging

**Abbreviations:** BOLD: Blood Oxygen Level Dependent; CEDM: Contrast Enhanced Digital Mammography; CEUS: Contrast Enhanced Ultrasound; DCIS: Ductal Carcinoma in Situ; DCE-MRI: Dynamic Contrast Enhanced Magnetic Resonance Imaging; DSA: Digital Subtraction Angiography; DOI: Diffuse Optical Imaging; DOS: Diffuse Optical Spectroscopy; DOT: Diffuse Optical Tomography; HIF: Hypoxia Inducible Factor; MMG: (x-ray) Mammography; MRI: Magnetic Resonance Imaging; MVD: Microvessel Density; NIR: Near Infrared; PAI: Photoacoustic Imaging; PAM: Photoacoustic Mammography; US: Ultrasound; VEGF: Vascular Endothelial Growth Factor.

## **Abstract**

Breast cancer is one of the major causes of morbidity and mortality in western women. Current screening and diagnostic imaging modalities, like x-ray mammography and ultrasonography, focus on morphological changes of breast tissue. However, these techniques still miss some cancers and often falsely detect cancer. The sensitivity and specificity for detecting the disease can probably be improved by focusing on the consequences of tumor angiogenesis: the increased microvessel density with altered vascular characteristics. In this review, various techniques for imaging breast tumor vasculature are discussed. Dynamic contrast enhanced magnetic resonance imaging is the most-used imaging modality in this field. It has a proven high sensitivity, but a low specificity and cannot be applied in all women. Moreover, it has problems with detecting ductal carcinoma in situ (DCIS). On the contrary, contrast enhanced digital mammography can detect DCIS, but requires the use of ionizing radiation. Contrast enhanced ultrasound provides real-time information about true intravascular blood volume and flow. However, this technique still has difficulties with discriminating benign from malignant tissue. Moreover, these three imaging modalities all require the injection of contrast agents. Two relatively new techniques that do not use external contrast agents are diffuse optical imaging and photoacoustic imaging. Both visualize the increased concentration of hemoglobin in malignant tissue and thereby provide a high intrinsic contrast. Especially photoacoustic imaging is a promising technique for breast imaging, since it combines high ultrasound-like resolutions with optical contrasts and it is safe and non-invasive.

## **Introduction**

Although the death rates of breast cancer have decreased with approximately 40% in the last 20 years (1-2), breast cancer is still one of the major causes of morbidity and mortality in western women aged over 40 years. Worldwide, every year more than 1,300,000 women are diagnosed with breast cancer and annually, about 450,000 women die from this disease (2). The decrease in death rates is, in addition to an increased specialization of care and widespread availability of modern treatments, most likely due to the screening programs that started in the late 1980's (2). Screening programs focus on an early detection of breast cancer, since the earlier the stage of the disease at detection, the earlier interventions can be applied and the better the survival chance (1). Currently, the imaging modalities that are mostly used for screening and diagnostic purposes are x-ray mammography (MMG) and ultrasonography (US). These modalities visualize anatomic features of breast tissue in order to discriminate malignant from benign tissue. However, both in screening and diagnostic imaging programs, breast cancers are regularly missed and often falsely detected (3-5). The sensitivity numbers for screening mammography lie between 70% and 90% (6) and, although the numbers found in the literature are highly varying, the specificity mostly does not exceed 90% (6). While the use of ultrasonography as an adjunct to x-ray mammography can improve the sensitivity in women with dense breasts from 73% to 85%, the combined specificity (40%) in this population is even lower than that of x-ray mammography alone (6-7). This might be an indication that focusing mainly on anatomical features is not sufficient for early breast cancer

detection. Besides, tissue architecture does not provide enough information about the nature of the tumor, for example whether it is prone to become invasive, to grow or to metastasize.

80

For a breast tumor to develop and grow, certain functional changes to breast tissue are required. Those functional changes occur well before any morphologic alterations are visible on conventional x-ray mammography or ultrasound (8-9). One example of such a change is the increase in vascularization that is required for a tumor to grow beyond a few millimeters (10). The best-known imaging modality that aims at visualizing this tumor vasculature is Dynamic Contrast Enhanced Magnetic Resonance Imaging (DCE-MRI). In breast cancer diagnosis, DCE-MRI is mostly used as an additional imaging modality when the combination of x-ray mammography and US does not provide sufficient information or cannot appropriately be applied. The sensitivity of DCE-MRI has proven to exceed the sensitivity of x-ray mammography and US, applied solely as well as in combination (11-13). However, MRI has quite some limitations that make it inappropriate as a first-  
90 line imaging modality. MRI suffers, for example, from a low specificity and high costs and cannot be applied on, amongst others, pregnant women or women with metallic implants (12). The high sensitivity of DCE-MRI proves that imaging the tumor's vasculature can indeed provide information about the malignant characteristics of tissue. However, there is a search for a new modality that overcomes the limits of the currently used methods. In this review, we will provide an overview of various breast imaging modalities that aim at visualizing the tumor's vasculature. Amongst these are dynamic contrast enhanced MRI (DCE-MRI), contrast enhanced digital mammography (CEDM), contrast enhanced ultrasound (CEUS) and diffuse optical imaging (DOI). We will highlight their working principles, merits and costs, while introducing a relatively new, non-invasive imaging technique that has potential in this field, namely photoacoustic mammography (PAM).

## 100 **Tumor angiogenesis**

~~Angiogenesis is a process in which new blood capillaries develop by sprouting and branching from existing ones~~  
(14-16) Angiogenesis is the process in which new blood capillaries are developed by sprouting and branching from existing ones (14-16). Since the diffusion limit for oxygen is only 100-200  $\mu\text{m}$  (14,16), rapidly expanding tumors, which are dependent on oxygen diffusion from the normal vasculature, become hypoxic and acidic and

eventually die (14-15). Therefore, gaining access to the host vascular system by the formation of blood vessels is one of the critical factors for tumor survival and expansion (14,17).

110 Tumor angiogenesis is linked to a switch in the equilibrium between positive and negative angiogenic regulators (17). Before this angiogenic switch tips the balance to the side of the pro-angiogenic factors, tumors are in their dormant phase and no angiogenic processes occur. Due to the lack of oxygen and nutrients, the cellular proliferation rate is balanced by the apoptotic rate, and the tumor is unable to grow beyond a few millimeters (8,14). However, the starving and hypoxic tumor cells express high levels of (amongst others) hypoxia inducible factor (HIF), which induces the release of pro-angiogenic growth factors like vascular endothelial growth factors (VEGFs) (15,18). These pro-angiogenic growth factors switch the equilibrium to the angiogenic side and initiate the formation of new capillaries (14). Until this stage, angiogenesis is a normal physiological process that also occurs in wound healing (19-20). In the normal angiogenic processes, there is a tight balance between pro-angiogenic and anti-angiogenic signals, allowing the new vessels to mature and become stable (17-18). On the contrary, in tumor angiogenesis, the loss in balance between positive and negative signals causes the vessel-growth to occur without stopping, enabling the constant growth of new tumor blood vessels. This supports rapid cell proliferation and permits a tumor to expand in mass (17-18). The resulting irregular and tortuous shape of  
120 the vessels and the abundant presence of shunts cause an abnormal and inefficient perfusion. The fact that tumor-associated capillaries lack sphincters and pericytes makes them largely independent from the normal mechanisms of flow-regulation. Moreover, fenestrated endothelial cells and tumor cells form the vessel lining and a basement membrane is missing, which causes tumor vessels to be more permeable than normal capillaries (14,16-17).

Imaging of tumor angiogenesis can focus on various stages of the angiogenic process. In molecular imaging techniques, the focus is on the molecules that are involved in angiogenesis (21). In this review, the focus is on imaging techniques that visualize the results of the angiogenic processes: an increase in vascularization with altered vascular properties. Currently, the gold standard for measuring this end product of angiogenesis is a  
130 histological estimation of microvessel density (MVD) in which the average number of microvessels within a microscopic field is quantified (22). Assessing the microvessel density is an invasive method and, besides,

cannot be used to determine the vascular properties. Moreover, MVD measures will often overestimate or underestimate the degree of angiogenesis, since tumors are heterogeneous and MVD measures will vary according to the location from which the biopsy is taken (22-23). Therefore, the search is for a non-invasive method that will provide clinically relevant information about the tumor's vasculature.

### **Magnetic Resonance Imaging (MRI)**

Magnetic Resonance Imaging (MRI) techniques for assessing tumor angiogenesis can be divided into two classes: those that do not and those that do require exogenous contrast agents (22). The first class comprises, amongst others, blood oxygen level dependent (BOLD) imaging. This technique was initially used for functional brain imaging, but the fact that it can measure tissue blood flow and vasoreactive responses, makes it also a potential candidate for imaging tumor vasculature (22,24). BOLD imaging makes use of the fact that the oxygenation state of the blood alters its magnetic properties. Since deoxyhemoglobin is inherently paramagnetic, a higher amount of deoxyhemoglobin causes shortening of the T2\* signal (the spin-spin relaxation time) (22,25-26). However, the changes in MR contrast are very small and require special statistics to be quantified. Moreover, the tissue needs to be challenged to induce a change in the deoxyhemoglobin and oxyhemoglobin ratio (26). In cancer tissue the provocation is achieved by inhalation of high concentrations of oxygen or carbogen (22,26). The hereby-induced oxygen saturation causes blood vessels to dilate and blood flow to increase: the result is an increased amount of oxygenated and a decreased amount of deoxygenated blood, leading to an increased MRI signal (22,25-26). It is hypothesized that healthy breast tissue induces a significant BOLD response, while the BOLD response in malignant tissue is insignificant (24). Currently, this method suffers from susceptibility artifacts, a poor resolution and is influenced by body temperature and medication. Besides, the inhalation of the carbogen gas mixture can be cumbersome and some patients feel uncomfortable to lie in the magnet with a breathing apparatus. Those limitations, together with its complexity and poor reproducibility make that there is no widespread clinical use of the BOLD technique in breast imaging (22).

Dynamic contrast enhanced MRI (DCE-MRI), which does require the injection of contrast agents, is the most-used imaging technique for visualizing breast tumor vasculature. It is often used as an additional method to x-ray

mammography and ultrasonography and is usually referred to as breast MRI. In DCE-MRI, a contrast agent that  
160 shortens the T1 recovery time (the spin-lattice relaxation time) is injected into the blood stream. This contrast  
agent is mostly a low molecular weight contrast medium like gadolinium.

In areas with greater vessel density, contrast enhancement can be observed by using the appropriate imaging  
parameters. Morphologic information, for example the type of enhancement, mass shape and margins and the  
internal architecture are of importance for differential diagnosis (27) as can also be seen in Figure 1a. Since the  
structure and permeability of the tumor vasculature are altered, the local kinetic behavior of the contrast is also  
altered (27): the low molecular weight contrast media that leak slowly from the normal vasculature, diffuse more  
rapidly out of the tumor vessels. This results in the characteristic contrast dynamics associated with tumor  
vascularization: a rapid initial wash-in of contrast followed by wash-out on delayed images (22,27) as can be  
seen in Figure 1b. Benign lesions are more associated with an initial increase in contrast followed by either  
170 progression or stabilization of contrast enhancement on delayed images (28). Indeed, contrast enhancement and  
kinetic parameters in DCE-MRI have been shown to correlate with histopathologic measures for neo-  
angiogenesis (29)

Figure 1a-b

The advantage of MRI is that it does not make use of ionizing radiation. Besides, DCE-MRI exhibits an  
excellent soft tissue resolution (voxel size  $< 1 \text{ mm}^3$ ) (27) and uses a tomographic imaging principle (12-13).  
DCE-MRI has a very good sensitivity for invasive carcinoma compared to x-ray mammography and ultrasound  
imaging (12,28,30) with sensitivity numbers near 100% being reported (12,31). The sensitivity is not impaired  
by the density of the fibroglandular tissue, nor by scar tissue, radiation therapy and the presence of breast  
implants (27). However, the enhancement characteristics of DCE-MRI are unreliable for ductal carcinoma *in situ*  
180 (DCIS). Less than 70% of DCIS lesions show the characteristic rapid enhancement (27,30). In fact, the kinetics  
of the contrast enhancement of DCIS correspond more to benign lesions than to malignancies, which lowers the  
sensitivity of the technique for diagnosing DCIS (27,30). One of the possible explanations is that DCIS is not  
associated with a notable angiogenic activity, at least not to the extent that it can be measured with DCE-MRI  
(27). However, the sensitivity for high-grade DCIS is still higher for MRI than for x-ray mammography (32).

There are numerous disadvantages with respect to MRI breast cancer imaging. Firstly, the method cannot be used in claustrophobic patients, pregnant patients and in patients with pacemakers or implanted non-titanium metallic clips (12). Secondly, it is a time-consuming and expensive method with a low throughput. An MRI investigation costs about five times the amount of a screening x-ray mammography (3,33). Thirdly, the high signal intensity of fat may obscure the lesion of interest. To overcome this, specific fat suppression sequences should be used, but they require an increased scanning time (28). Finally, for DCE-MRI the intravenous application of a paramagnetic contrast agent is mandatory (3) and, although gadolinium has proven to be safe, every injection of contrast agent is associated with risks of adverse reactions (34).

Another disadvantage of DCE-MRI is its low specificity with numbers below 50% reported (35-36). Not only the number of false positives is high, but with DCE-MRI a risk for overestimation in size, stage and ductal spread exists (3,12,30,37). The lack in specificity of breast DCE-MRI is mainly caused by the fact that the contrast in DCE-MRI not only depends on the local amount of contrast agent and therefore on the vessel density, but also on the pulse-sequence settings and the characteristics of the contrast agent. Specifically the T1 contrast of the pulse-sequence used, the baseline T1 recovery of different tissues and of the contrast agent, and the diffusion of the contrast agent are of influence on the measured contrast (23). The tissue even shows highly variable enhancement in normal breast parenchyma, which is referred to as background enhancement and depends on the patients' hormonal status (27-28,38). By far the most important source of false positive diagnoses is the fibroadenoma. This benign tumor demonstrates signal enhancement patterns similar to that of invasive cancer (39-40) reflecting the significant overlap in the number of microvessels between invasive ductal carcinomas and fibroadenomas (40). Although there are differences in the microvessel distribution within the lesions (40-41), the fact that the MRI contrast agents leak out of the vasculature makes it very difficult to differentiate intravascular from extravascular contrast and therefore to visualize the small differences in microvessel distribution.

## 210 **Contrast enhanced digital mammography (CEDM)**

X-ray mammography is the only breast screening modality that has been proven to reduce the death rates from breast cancer (42). However, this morphology sensitive technique suffers from quite some limitations. Breast

cancers are still missed by mammography (42-43) and its accuracy is limited in dense breasts where it suffers from a low contrast between benign and malignant tissue (44-45). Imaging tumor angiogenesis with mammography has been investigated more than twenty years ago, using a technique called digital subtraction angiography (DSA) (45-46). In this technique, a contrast medium (usually iodine) was intravenously administered, followed by a set of radiographic views of the breast using an image intensifier system. It was thought that the presence of a blush (a localized prolonged retention of contrast medium) accompanied by abnormal vessel characteristics was indicative for malignant lesions (45-46). Indeed, abnormal tumor vasculature could be visualized with both planar DSA and contrast enhanced x-ray computed tomography (CT). The results of these techniques have been in close agreement with biopsy and pathologic findings (44-47). However, both techniques did not prove to be clinically useful (43), mainly because of the high radiation exposure (45-46), the lengthy imaging duration and implementation problems (48).

Digital mammography systems have been developed to enable rapid imaging and image processing. Those systems are therefore able to employ sophisticated techniques for imaging and localization of early breast cancer (48-50). One of these techniques is contrast enhanced digital mammography (CEDM) in which, like in DCE-MRI and DSA, an intravenous contrast agent is administered to enhance malignant breast lesions (42). The most-used contrast agent is iodine, which provides a highly differentiating attenuation compared to tissue. Besides, iodine is non-toxic and has proven to be useful and safe in other vascular imaging procedures (48-49).

Two different techniques of CEDM exist: the dual-energy technique and the temporal or dynamic subtraction technique (42-43,47,49-50). In the temporal subtraction technique, the high-energy images are obtained before and at varying time points after the injection of contrast medium (Figure 2). Afterwards, the pre-contrast image is subtracted from the post-contrast images (50). This technique can be compared with DCE-MRI and DSA, since it makes it possible to analyze the kinetic behavior of the contrast agent at the location of the lesion (50). The images are acquired over several minutes with only slight breast compression, which makes the method highly prone to motion and displacement artifacts. Since the pre-contrast and post-contrast images need to be registered with high accuracy, motion artifacts have an impact on the final contrast (47-48,50-51). To overcome this problem, the breast can be more tightly compressed, which is uncomfortable for the patient and might also



240 limit the blood flow and affect contrast enhancement (42,51). Since the breast cannot be repositioned, only one view can be obtained with a single injection (42-43). Therefore, the 3D location of an abnormality cannot be estimated with temporal CEDM (42).

#### Figure 2

In dual-energy CEDM, images are obtained by using energies both below and above the k-edge (33.2 keV) of the contrast agent (42-43,50-51). This technique makes use of the energy dependence of the x-ray attenuation through different 'materials', which are in this case iodine and soft tissue (Figure 3). Usually, for the low energy source a molybdenum target at peak-voltages of 22-33 kV is used in combination with a molybdenum filter; for the high-energy source, this is a rhodium target at 44-49 kV in combination with a rhodium filter (43). A weighted subtraction of the two images is applied to minimize the visibility of breast tissue, while maximizing  
250 the visibility of iodine contrast agent. Therefore, this technique enhances the areas with contrast uptake (43,50). Compared to the temporal technique, the major advantage of dual-energy CEDM is its reduced sensitivity to motion artifacts, since the time between the different exposures is very short (50). Because this technique does not require matching of pre-contrast and post-contrast images, multiple views can be obtained, making a more exact localization of the lesion possible (42-43,50). Besides, contrast injection can be performed before breast compression is applied, circumventing the problem of influencing the vascular dynamics by breast compression (42,52). The fact that low and high energy views are required makes that the radiation exposure is higher for dual energy CEDM than for temporal CEDM (50). Therefore the number of images performed after contrast injection is limited and no information about the kinetics of enhancement can be obtained (50). Finally, since iodine contrast is present in both the low and high energy images, this approach can cause a small loss of iodine  
260 signal after the weighted subtraction techniques (42).

#### Figure 3

Preliminary studies have shown that CEDM might be a useful (adjunctive) technique for diagnosing breast cancer in women with dense breasts (44), showing sensitivity numbers above 80% and excellent correlations between histological tumor size and the size of contrast enhancement (50). Specificity numbers vary between 60% (looking only at enhancement) and 90% (including morphologic information) (42,49). The fact that especially the low-energy source can also visualize microcalcifications makes the dual-energy CEDM potentially

more sensitive to DCIS detection than DCE-MRI (43). Because of the widespread availability of digital mammography, CEDM will become highly accessible and relatively inexpensive, especially when it is compared to MRI (44). No studies have been performed with respect to the comparison of CEDM and DCE-MRI and it remains to be seen if CEDM can exceed the sensitivity and resolution of MRI (42-43,50). The most important difference with MRI is that CEDM is a projection technique; even with the injection of contrast agent superimposition of adjacent breast tissue might influence sensitivity and specificity numbers. Therefore it is not expected that ordinary CEDM will replace MRI in the near future (42).

Digital breast tomosynthesis (DBT) is another relatively new digital x-ray technique in which a stationary detector and a moving x-ray source are used to obtain different projections under various angles (49,52). In this way, fast three dimensional information can be obtained (42). Combining CEDM and digital breast tomosynthesis potentially overcomes most of the limitations of the former used in isolation. Both breast cancer morphology and vascular information can be provided, superimposition problems may be overcome and less compressive force needs to be applied. Indeed, in a preliminary pilot study, Chen et al. showed the possibility of combining both techniques (47). This combined technique is still very new and requires further examination before conclusions about its potential can be drawn (47).

### **Doppler ultrasound imaging and contrast enhanced ultrasound imaging (CEUS)**

Breast ultrasound imaging is widely used as an adjunct to mammography. Ultrasound is an excellent method for assessing palpable abnormalities, differentiating between cystic and solid lesions, and classifying solid masses. Moreover, ultrasound imaging is the method of choice to guide core needle biopsies (13) and can improve the characterization of solid breast lesions as benign or malignant (53). However, the specificity of this technique is quite low, it has limited ability to distinguish little lesions from fat lobules and suffers from an examiner dependent accuracy (54).

In an attempt to improve the diagnostic accuracy of ultrasound, tumor vascularity has been assessed non-invasively with both color Doppler and power Doppler ultrasonography (55-56). Color Doppler ultrasonography is based on the Doppler frequency shift between the transmitted and received acoustic pulse due to the

movement of the blood cells through the measured volume (57). This method can evaluate blood flow and it is therefore useful in the differential diagnosis of breast lesions (57-58). However, the technique suffers from an angular dependency and poor signal to noise ratios (57), making it often unable to evaluate flow signals from small vessels (< 1 mm) in which the flow is low (3-5 cm/s) (56). This flow approximately equals the tissue motion velocity, making the technique highly sensitive for motion artifacts caused by for example patient breathing (59-60).

300 To overcome these limitations, power Doppler imaging was introduced in which the color map shows the integrated power of the Doppler signal. Power Doppler imaging is less prone to noise artifacts since noise has a very low power with respect to the information containing signal (57). Power Doppler ultrasound is also much less angular dependent since the power in the Doppler spectrum is related to the number of red blood cells producing the Doppler shift (57). These aspects increase the sensitivity of Doppler ultrasound: smaller frequency shifts and smaller numbers of intravascular reflectors can be measured (56). Indeed, power Doppler ultrasonography has a higher sensitivity (>75%) and specificity (>75%), and therefore a higher diagnostic accuracy than color Doppler ultrasonography in the evaluation of palpable breast lesions (55-56,61). Although ultrasound Doppler images are on average statistically different between benign and malignant lesions, groups overlap and consequently the technique has a weak diagnostic performance (53,62). Power Doppler ultrasound  
310 imaging still exhibits a low sensitivity for detecting flow in small tumor vessels (< 200  $\mu$ m) and cannot distinguish small Doppler signals from background disturbances (53,56,58).

A newer approach in ultrasound imaging of angiogenesis is contrast-enhanced ultrasound (CEUS). Ultrasound contrast agents with microbubbles can be used to increase vascular signals in ultrasonography (60). The micron-sized, gas-filled microbubbles are able to produce a 15-25 dB increase in the echo intensity of the blood flow signal (53). This improves the Doppler assessment of the presence, morphology and flow of tumor microvessels in the breast (54,58,60). The first microbubbles were simple air bubbles wrapped in an outer shell of protein or lipid, while current microbubbles encapsulate insoluble gas to make them remain more stable in the blood (63). Microbubbles not only reflect sound at the fundamental (incoming) frequency, but also generate higher

320 harmonics. This makes them suitable for harmonic imaging in addition to color and power Doppler ultrasonography (63).

Differences in contrast enhancement intensity and kinetics have been observed between benign and malignant lesions. CEUS made detection of smaller vessels possible and improved the diagnostic accuracy, sensitivity and specificity of Doppler ultrasonography (23,53,56,58,60,63). Sensitivity and specificity numbers both exceeding 95% are reported (56). One advantage of CEUS is that it is a real-time imaging method that is relatively inexpensive and readily repeatable (63). The major difference with other contrast-enhanced imaging techniques, like DCE-MRI and CEDM, is that the microbubbles are true intravascular contrast agents: they do not diffuse into the extravascular compartment. Therefore, CEUS is a useful technique for measuring true blood flow and volume (23,58,64). Especially with the use of newer contrast imaging techniques (like pulse inversion harmonic  
330 imaging and intermittent power Doppler), the enhancement parameters can give information about the microvessel density, the amount of shunting of the vessels and the heterogeneity of the vasculature (23,53-54,60). An example of a CEUS image can be seen in Figure 4.

On the other hand, CEUS cannot provide any information on the permeability of the tumor capillaries (23,58) and it presents some more limitations. Firstly, the microbubble contrast agents are present in the tumor vessels for a short time only, which hampers full breast scanning within the few minutes before the contrast agent washes out. Therefore, often multiple doses of contrast material are required to visualize all vascular phases of the contrast agent (23,58,63). Secondly, CEUS cannot provide information about the entire breast like in DCE-MRI (23,63). Thirdly, the assessment of breast CEUS is subjective and not all studies have shown significant  
340 correlations between the CEUS image and histological microvessel density. The higher specificity of this technique sometimes occurred at the cost of a weaker sensitivity (53,58,60). Finally, as was the case with DCE-MRI, contrast-enhancement can also be observed in some benign lesions, like hypervascularized inflammations and fibroadenoma. Those lesions may be mistaken for malignancy, while on the other hand low-grade hypovascular carcinoma might be diagnosed as benign tissue (56,60).

Figure 4 a-c

### **Diffuse optical imaging (DOI)**

350 Far-red and near infrared (NIR) light (650-1100 nm) can travel across several centimeters of breast tissue due to low absorption and scattering coefficients of soft tissue in this wavelength region (65). The diffuse transmittance or reflectance of NIR light can provide information about the local absorption and scattering coefficients of tissue (66). Hemoglobin is a strong intrinsic absorber of NIR light, which causes the absorption coefficient of blood vessels to be much higher than that of surrounding glandular and adipose breast tissue (67). Because of the angiogenic processes, the local concentration of hemoglobin is increased at malignant sites. Moreover, the oxygen saturation is decreased in rapidly expanding tumors due to their hypermetabolism (33). Tissue scattering can be increased by an increase in the number density and size of subcellular organelles (33) and both are altered in malignancies. Consequently, the absorption and scattering properties of light at the NIR wavelengths can give information about cell sizes, blood dynamics, total hemoglobin concentration and blood oxygen saturation parameters, which could reveal the presence of breast malignancies (33,68-69).

360 Diffuse optical imaging (DOI) can be applied using three distinct methods: continuous wave, time domain or frequency domain imaging. In the continuous wave approach, the transmission of continuously delivered NIR light across the breast is measured. This technique is relatively inexpensive and rather compact, but it suffers from some disadvantages. The detected intensity is, for example, highly dependent on surface coupling and measurements of the intensity at a single wavelength alone are not sufficient to differentiate absorption from scattering interactions (65,70-71). An example of a continuous wave DOI system for breast imaging is the Philips optical mammoscope (71), which was already tested for its feasibility in the late 1990's and proved to be able to detect a variety of inhomogeneities. ~~However, the specificity of this technique is still poor (69,71).~~ However, the specificity of this technique is still poor (69,71), with false positive rates up to 22% being reported in a group of women with proven breast malignancies (69).

370 In frequency domain measurements the light intensity is modulated at tens to hundreds of megahertz. In this case, information about the optical properties can be calculated from amplitude decay and phase shift measurements of the signal (65). In time domain methods, picosecond-pulsed laser light is used to measure the temporal distribution or times of flight of photons that exit the breast tissue to obtain information about optical properties of tissue (65,72). Time-domain and frequency domain measurements can theoretically express the

same information, but both have their advantages and disadvantages. Frequency domain systems are relatively inexpensive, easy to develop and provide fast temporal sampling. In time-domain imaging, the information content of the signal is greater than can currently be measured in the frequency domain: the frequency content of the time of flight distributions extends to several GHz and it is not yet possible to modulate high-intensity sources at such high frequencies (70). Moreover time-domain systems are far more sensitive than the frequency domain systems, making imaging at higher depths possible (70).

380 DOI for mammography can be divided in transillumination approaches and the so-called tomographic principles (65,70). In transillumination or planar imaging, source and detector pairs are arranged on opposite sides of the breast in order to obtain two-dimensional projection images of the tissue. This approach has advantages of easy implementation, easy reconstruction and comparable views to conventional mammographic images. However, this technique does not provide detailed information about the 3D spatial localization of the specific absorbers and usually requires breast compression (65). Currently, most research focuses on diffuse optical tomography (DOT), which applies DOI in a tomographic manner, usually in time (66,72) or frequency domain (33,73). Sources and detectors are placed over the available surface in order to record signals from multiple lines-of-sight across the entire volume (70). Hereby, 3D maps of the optical properties of the breast can be obtained (65,74). The disadvantages are that more powerful sources and more sensitive detectors are required, as are non-linear  
390 reconstruction algorithms (74).

In recent studies with respect to breast cancer diagnosis, it has been shown that DOI is able to differentiate between benign and malignant tissue optical properties as can be seen in Figure 5. In some cases, malignant lesions that were smaller than 1 cm in diameter could be discriminated from normal glandular tissue (33). This was primarily due to the higher hemoglobin contents, causing more light to be absorbed. However, also the scattering of light and the oxygen saturation suggested good discriminatory power (33,68-69,75). Advantages of DOI are the use of non-ionizing low energy electromagnetic radiation, continuous data acquisition and low price compared to MRI and x-ray mammography (65,68). Furthermore, DOT measurements can be applied with the patient in a prone position with reasonably good coverage of the breast, using only little breast compression (76-  
400 77). Molecular level information and submicroscopic structural information about the tissue function can be

obtained with DOI and diffuse optical spectroscopy (DOS) (33,76). In the optical imaging techniques, breast density seems not to be an issue, so it can also be used in younger women (68). The greatest strength of the optical imaging techniques is that the absorption of NIR light by hemoglobin can provide one of the highest intrinsic biological contrasts possible. Sometimes the contrast reaches levels up to 200%, compared to only 10% contrast in x-ray mammography (78).

Figure 5 a-e

410 A disadvantage is that the optical mammography techniques have low spatial resolutions. Due to multiple scattering of NIR light, the achievable resolution is degraded to near 5 mm within a few centimeter of tissue and worsens with depth (67,78). In order to moderately improve the spatial resolution, the number of sources and detectors should be (impractically) large (33). Another disadvantage of the DOT techniques is the difficulty of image reconstruction. An accurate quantification of optical properties relies heavily on the reconstruction algorithm and often a-priori information about the tumor and the surrounding tissue is required (33,67).

The clinical applicability of the optical imaging techniques is limited by the heterogeneity of the optical properties of breast tissue between and even within patients. Tumor tissue exhibits heterogeneous levels of vascularization and oxygen saturation. The interpatient variations and variations throughout the different phases of the menstrual cycle can exceed the differences between benign and malignant lesions (79-80). Static, single shot optical images do neither provide information about the altered vascular characteristics nor about the mechanical changes of the malignant breast tissue. Therefore, some research centers investigate the application  
420 of dynamic imaging techniques to characterize the optical properties of the tissue. In dynamic optical imaging, external dynamic stimuli are introduced to measure relative changes in the tissue optical properties. Stimuli can be chemical, mechanical or physiological (80-81). Although only few studies to the use of dynamic stimuli in DOI of malignancies were applied, the results are promising: the external stimuli made better differentiation between benign and malignant lesions possible (68,79-80).

Another approach is the use of fluorescent contrast agents in DOT. Those fluorescent agents may improve lesion contrast and might therefore be useful in the early detection of breast cancer (82-83). It has been shown that DOT using a low concentration of a non-specific fluorescent contrast agent (Indocyanine Green (82) or

430 Omocyanine (83)) is feasible and safe for breast cancer visualization in patients (82-83). However, the technique requires the injection of fluorescent agent prior to the study. Moreover, since the contrast agents are non-specific, normal tissue could also show contrast enhancement. Therefore, development of probes with more specific binding to relevant tissue components is required to make diffuse optical imaging using fluorescent contrast agents clinical applicable (83).

### **Photoacoustic imaging (PAI)**

The interactions of NIR light with tissue can provide a wealth of information about the tissue constituents, the presence of hemoglobin and the oxygen saturation of the blood. Therefore, imaging techniques that are based on the absorption of NIR light in tissue can provide high contrast between vascularized and non-vascularized tissue. In pure optical based imaging techniques the spatial resolution degrades significantly with depth (84). Photoacoustic imaging (PAI) is an upcoming technique that overcomes this limitation by combining optical 440 excitation with ultrasound detection, exploiting the thermoelastic effect that occurs upon absorption of pulsed light (85). With photoacoustic imaging, laser light in the NIR region is used for irradiating the tissue, like in optical imaging. The optical absorption of the pulsed laser light causes a local temperature increase of the tissue, followed by a thermal expansion leading to a pressure rise. The pressure relaxes as an ultrasound wave that propagates with minimal distortion to the surface where it can be detected using appropriate wideband ultrasound detectors (84-87). The time-of-flight, amplitude and peak to peak time of the photoacoustic signal depend on the amount of absorption of the laser light and on the size and position of the absorbing objects (88). Those aspects are dependent on the composition of the tissue and on the local amount of vascularization and blood oxygenation. Therefore, the increased concentration of hemoglobin provides the main source of optical (and therefore photoacoustic) contrast for breast malignancies relative to normal tissue (89). Because the 450 detected signal is not the highly scattered light, but the much less scattered ultrasound, the resolution of PAI is superior to that of DOI. With PAI, one can combine optical contrast with the resolution of ultrasound, without limitations of breast density, magnetic compatibility problems and the use of contrast agents or ionizing radiation (86,89-90). This technique allows the future combination of pure ultrasound and photoacoustic measurements in one system (91-92), providing both morphologic and functional information about the breast tissue, while with



photoacoustic spectroscopy information about the oxygen saturation of the blood can be obtained (93-94). Analogous to diffuse optical imaging, also in photoacoustic imaging external contrast agents can be used for better imaging of the tumor's vasculature. More specific and higher absorption of the NIR light at tumor vasculature can result in detection of smaller and deeper tumors. Recent studies with animal models show the possibilities of using external contrast agents for imaging tumor vascular networks. Examples of photoacoustic contrast agents are dyes such as Evans blue (95) and nanoparticles such as gold nanorods (96-97), gold nanobeacons (98) and carbon nanotubes (99).

Although it is possible to generate photoacoustic signals with intensity modulated continuous wave lasers (100), pulsed lasers are mostly used. Photoacoustic imaging using a pulsed laser usually has a higher signal to noise ratio and makes it possible to directly calculate the distance of the photoacoustic source from the detector (87). Different imaging configurations can be used for photoacoustic imaging. With one technique a focused ultrasound transducer is used for time-resolved detection of the photoacoustic waves. By scanning the transducer over the tissue, 3D information of the underlying tissue can be obtained (85,101). This technique is the easiest to implement, however it takes very long to scan large volumes and is therefore not useful for scanning the whole breast. For breast imaging, it is more convenient to use an array of unfocused ultrasonic transducers (85,101-102).

The maximum imaging depth is determined predominantly by light penetration in the breast, but is also influenced by the attenuation of the ultrasound. Mostly, light in the NIR region is used; NIR light penetrates relatively deep into tissue, while the absorption contrast of hemoglobin with respect to tissue remains high. The disadvantage of photoacoustic imaging is that, due to optical scattering and absorption, the maximum imaging depth is limited to about ~5 cm (with a resolution < 1 mm) (85). Since the attenuation of ultrasound increases with frequency, human tissue serves as a low pass filter: the ultrasound attenuation changes the amplitude and waveform of signals from more deeply positioned sources. By decreasing the central frequency of the ultrasound detector, one can detect signals from deeper structures. However, only detecting lower frequencies also degrades the spatial resolution of the system. Therefore, the interplay between detector frequency and bandwidth highly influences the detection characteristics of the photoacoustic system (84-85,87,103).

In the last years, several groups have studied the clinical utility of photoacoustic imaging in breast cancer diagnosis. Special instruments with different configurations have been developed to get the optimal resolution, imaging depth and contrast in breast tissue phantoms, small animals and healthy volunteers (88,102-106). An example of the latter is shown in Figure 6 in which the microvasculature of the healthy breast can be clearly visualized with both high contrast and excellent resolution.

Figure 6 a-b

Also different clinical studies have been performed that showed the possibility to produce high-resolution clinical photoacoustic images suitable for the morphologic analysis of the tumor angiogenesis (89,107-109). An example of this can be seen in Figure 7.

There are considerable challenges evidenced by optical attenuation in the skin and breast tissues, acoustic artifacts and sensitivity and bandwidths of the transducer array (89,102). The only clinical studies that are performed use small patient groups (89,102,107-108). Therefore, although the first clinical results of this technique are promising, it needs to be investigated if the positive results can be repeated in a larger population in order to get more information about the feasibility of photoacoustic breast cancer imaging.

## **Discussion**

Techniques that focus on an altered tissue morphology, such as x-ray mammography and ultrasonography are often not able to discriminate benign from malignant lesions and often miss breast cancers. In order to improve the diagnostic accuracy of breast cancer detection, we believe that imaging modalities should focus on the results of tumor angiogenesis: a locally increased, but heterogeneous, microvessel density with irregular and highly permeable vessels. This review described the use of Magnetic Resonance Imaging (MRI), contrast enhanced digital mammography (CEDM), ultrasound techniques, diffuse optical imaging (DOI) and photoacoustic imaging (PAI) for imaging the breast tumor's vasculature. In Table 4 I, the advantages and disadvantages per image modality are shown. These properties will be discussed in more detail in following sections.

Table I

### *Sensitivity and Specificity*

510 Sensitivity and specificity numbers for various techniques are shown in Table 2 II. Obviously, the values are highly varying throughout the literature. For example, Sorelli et al. (110) reported a sensitivity of 100% and a specificity of 37.5% for contrast enhanced ultrasound in the evaluation of palpable breast lesions, while Zhao et al. (54) reported a sensitivity of 86.7% and a specificity of 96.7% for this same technique. The variation in sensitivity and specificity can be caused by: 1) differences in the way the technique is being performed (31); 2) different evaluation criteria (35); 3) different study-populations (110-112); and 4) the difference in the physician's knowledge about earlier imaging results (113). Therefore, the sensitivity and specificity numbers given in this review are only rough indicators of the performance of a technique.

### Table II

### 520 *Diagnosis*

When referring to sensitivity and specificity numbers, one should differentiate between screening and diagnostic imaging techniques. For diagnostic imaging of the breast's vasculature, dynamic contrast enhanced MRI (DCE-MRI) is the only technique that finds widespread clinical use. Indeed, it has been proven that the sensitivity of breast cancer diagnosis increased when DCE-MRI was used as an adjunct to x-ray mammography in case the mammogram proved to be inconclusive (114). In addition to DCE-MRI, CEDM and CEUS also proved to be useful adjuncts to conventional imaging techniques (44,54). However, they do not (yet) find widespread clinical use, because of several disadvantages with respect to DCE-MRI. Sensitivity numbers of both CEDM and CEUS do not exceed those of DCE-MRI, while CEDM does require the use of ionizing radiation and both, currently, cannot provide a full 3D view of the breast. Diffuse optical imaging (DOI) and photoacoustic imaging (PAI) are  
530 still in early phases of development, but preliminary promising results on breast cancer diagnosis have been published (89,107,115). Those techniques have the advantages that they do neither require the external injection of contrast agents, nor use ionizing radiation. Moreover, in contrast to DCE-MRI, DOI and PAI can be applied in almost all women. Especially photoacoustic imaging is promising, since it combines the high contrast of optical imaging with the good resolution of ultrasound.

One major difference between DCE-MRI and CEDM on the one side and CEUS, DOI and PAI on the other side is that both DCE-MRI and CEDM not only provide information about the local vessel density, but also about the leakage of contrast agent from the vasculature to the surrounding tissue. Therefore, with those techniques crucial information on the permeability of the microvessels can be obtained. However, leakage of contrast agent out of the vasculature makes it impossible to measure true blood volume and flow and limits the differentiation between fibroadenoma and invasive carcinoma (40). This can be one of the reasons that the specificity of DCE-MRI is rather low. CEUS, DOI and PAI, on the other hand, do image true intravascular space, because both microbubbles and hemoglobin do not leak out of the tumor vasculature. Especially with high resolution CEUS and PAI it should be possible to differentiate fibroadenoma from malignancies based on the different microvessel distributions within the two lesion types. Although DOI and PAI lack the crucial information about the permeability of the microvessels, it is currently being investigated if dynamic optical or photoacoustic imaging can provide extra diagnostic information on the tissue's and microvessels characteristics. This information could possibly increase the discriminating power of the techniques, without losing the advantages of imaging true intravascular contrast agent (68,79-80).

550 *Screening:*

We have seen that imaging the tumor's vasculature as an adjunct to conventional imaging can provide extra information on the nature of the lesion, but it remains to be seen if those vascularization-imaging techniques can also be used as a screening modality. Currently, x-ray mammography is the method of choice for breast cancer screening since it is the only method that proved to reduce breast cancer death rates. This method is relatively easy to apply, cheap and fast, but it suffers from limitations of which one of the most important is the use of ionizing radiation. The specificity of screening x-ray mammography is too low: from the Dutch women that were referred for further diagnosis based on their first screening mammogram in 2007, only 30% had a true breast malignancy (116). Moreover, x-ray mammography is a relatively uncomfortable method that requires rather large pressures to compress the breast. None of the other described imaging modalities is currently used for breast cancer screening in the conventional screening population. For obvious reasons, CEDM could not replace x-ray mammography, since it requires even more ionizing radiation and the injection of contrast agents.

CEUS cannot provide a whole breast view and is too performer-dependent. Even DCE-MRI has not yet proven to be a adequate screening tool in isolation, especially because of its rather low specificity and lengthy measurement duration (117).

570 DCE-MRI is, on the other hand, used for screening young women with a high risk for developing breast cancer (118). Those women cannot have an annual screening mammogram for two major reasons: 1) The overall life-time dose of x-rays would be unacceptably high, especially since those women are more susceptible for developing malignancies (118); and 2) their denser breasts make the interpretation of the x-ray mammogram difficult, which lowers sensitivity and specificity numbers (117). In Table III, the sensitivity and specificity numbers for screening the high-risk population are shown.

#### Table III

The disadvantage of using DCE-MRI for annual screening in this population is that the method is time-consuming, expensive and not applicable in women who are pregnant or have metallic implants. Although more clinical data needs to be collected, DOI and PAI are potentially good methods for screening women with a high risk for breast cancer. Those methods are non-invasive, fast, can be applied in a prone position with relatively low compression and do neither require the use of ionizing radiation nor contrast agents.

580 It still has to be investigated if the information about the tumor's vasculature alone is specific enough to discriminate benign lesions from early signs of breast cancer. It was seen in both DCE-MRI and CEDM that specificity and sensitivity numbers significantly improved when both the contrast enhancement and tissue morphology were used as evaluation criteria (35,42). In addition, the variations in optical properties of breast tissue within and between women often exceed those between benign and malignant tissue as was seen in DOI (79-80). Therefore, also PAI might have problems with differentiating benign tissue from early signs of breast cancer in the screening situation. However, with the future possibility of applying ultrasound transmission imaging and PAI in one system (119), the discriminating power is expected to be increased.

## Conclusions

590 Focusing on the tissues vasculature is a useful adjunct to the conventional imaging techniques in the diagnosis of breast cancer. Nowadays, Dynamic Contrast Enhanced Magnetic Resonance Imaging (DCE-MRI) is the only method that finds widespread clinical use. However, Diffuse Optical Imaging (DOI) and Photoacoustic Imaging (PAI) are relatively new techniques that have great potential in this field and partly overcome the disadvantages of DCE-MRI. PAI might also be useful in the annual screening of women with a high risk for breast cancer, especially when it is combined with ultrasound.

### **Conflict of interest**

W.S., T.v.L. and S.M. have financial interest in PA Imaging Holding BV, which however did not support this work.

### **Acknowledgements**

600 The financial support of the Agentschap NL Innovation–Oriented Research Programmes (IOP) Photonic Devices under the HYMPACT Project (IPD083374) is gratefully acknowledged. We thank Dr. Bezooijen from the radiology department of the Medisch Spectrum Twente hospital for the DCE-MRI images, and Dr. Balleyguier, Dr. Dromain, Prof. Kruger and Dr. Choe for the permission to reprint their Figures.

## References

- 1 UK, C. R. CancerStats report - Breast Cancer UK. (2009).
- 2 Tirona, M. T., Sehgal, R. & Ballester, O. Prevention of breast cancer (part I): epidemiology, risk factors, and risk assessment tools. *Cancer Invest* 28, 743-750 (2010).
- 3 Heywang-Kobrunner, S. H., Schreer, I., Heindel, W. & Katalinic, A. Imaging Studies for the Early Detection of Breast Cancer. *Deutsches Arzteblatt International* 105, 541-U529 (2008).
- 610 4 Bonneux, L. Advantages and disadvantages of breast cancer screening: time for evidence-based information. *Ned Tijdschr Geneeskde* 153, A887 (2009).
- 5 Nothacker, M., Duda, V., Hahn, M., Warm, M., Degenhardt, F., Madjar, H., Weinbrenner, S. & Albert, U. S. Early detection of breast cancer: benefits and risks of supplemental breast ultrasound in asymptomatic women with mammographically dense breast tissue. A systematic review. *Bmc Cancer* 9, - (2009).
- 6 Vainio, h. & Bianchini, F. in *IARC Handbooks of cancer prevention* Vol. 7 (IARCpress, Lyon, 2002).
- 7 Pediconi, F., Catalano, C., Roselli, A., Dominelli, V., Cagioli, S., Karatasiou, A., Pronio, A., Kirchin, M. A. & Passariello, R. The challenge of imaging dense breast parenchyma: is magnetic resonance mammography the technique of choice? A comparative study with x-ray mammography and whole-breast ultrasound. *Invest Radiol* 44, 412-421 (2009).
- 620 8 Ribatti, D., Nico, B., Crivellato, E., Roccaro, A. M. & Vacca, A. The history of the angiogenic switch concept. *Leukemia* 21, 44-52 (2007).
- 9 Bluff, J. E., Menakuru, S. R., Cross, S. S., Higham, S. E., Balasubramanian, S. P., Brown, N. J., Reed, M. W. & Staton, C. A. Angiogenesis is associated with the onset of hyperplasia in human ductal breast disease. *British Journal of Cancer* 101, 666-672 (2009).
- 10 Daldrup-Link, H. E., Simon, G. H. & Brasch, R. C. Imaging of tumor angiogenesis: Current approaches and future prospects. *Current Pharmaceutical Design* 12, 2661-2672 (2006).
- 11 Hagen, A. I., Kvistad, K. A., Maehle, L., Holmen, M. M., Aase, H., Styr, B., Vabo, A., Apold, J., Skaane, P. & Moller, P. Sensitivity of MRI versus conventional screening in the diagnosis of BRCA-associated breast cancer in a national prospective series. *Breast* 16, 367-374 (2007).
- 630 12 Uematsu, T., Yuen, S., Kasami, M. & Uchida, Y. Comparison of magnetic resonance imaging, multidetector row computed tomography, ultrasonography, and mammography for tumor extension of breast cancer. *Breast Cancer Research and Treatment* 112, 461-474 (2008).
- 13 Vassiou, K., Kanavou, T., Vlychou, M., Poultisidi, A., Athanasiou, E., Arvanitis, D. L. & Fezoulidis, I. V. Characterization of breast lesions with CE-MR multimodal morphological and kinetic analysis: Comparison with conventional mammography and high-resolution ultrasound. *Eur. J. Radiol.* 70, 69-76 (2009).
- 14 Cuenod, C. A., Fournier, L., Balvay, D. & Guinebretiere, J. M. Tumor angiogenesis: pathophysiology and implications for contrast-enhanced MRI and CT assessment. *Abdominal Imaging* 31, 188-193 (2006).
- 15 Oostendorp, M., Post, M. J. & Backes, W. H. Vessel Growth and Function: Depiction with Contrast-enhanced MR Imaging. *Radiology* 251, 317-335 (2009).
- 640 16 Carmeliet, P. & Jain, R. K. Angiogenesis in cancer and other diseases. *Nature* 407, 249-257 (2000).
- 17 Bergers, G. & Benjamin, L. E. Tumorigenesis and the angiogenic switch. *Nature Reviews Cancer* 3, 401-410 (2003).

- 18 Naumov, G. N., Folkman, J., Straume, O. & Akslen, L. A. Tumor-vascular interactions and tumor dormancy. *Apmis* 116, 569-585 (2008).
- 19 Furuya, M., Yonemitsu, Y. & Aoki, I. III. Angiogenesis: Complexity of Tumor Vasculature and Microenvironment. *Current Pharmaceutical Design* 15, 1854-1867 (2009).
- 20 Peirce, S. M. Computational and mathematical modeling of angiogenesis. *Microcirculation* 15, 739-751 (2008).
- 21 Josephs, D., Spicer, J. & O'Doherty, M. Molecular imaging in clinical trials. *Target Oncol* 4, 151-168 (2009).
- 22 Barrett, T., Brechbiel, M., Bernardo, M. & Choyke, P. L. MRI of tumor angiogenesis. *Journal of Magnetic Resonance Imaging* 26, 235-249 (2007).
- 650 23 Marcus, C. D., Ladam-Marcus, V., Cucu, C., Bouche, O., Lucas, L. & Hoeffel, C. Imaging techniques to evaluate the response to treatment in oncology: Current standards and perspectives. *Critical Reviews in Oncology Hematology* 72, 217-238 (2009).
- 24 Rakow-Penner, R., Daniel, B. & Glover, G. H. Detecting blood oxygen level-dependent (BOLD) contrast in the breast. *J Magn Reson Imaging* 32, 120-129 (2010).
- 25 Jin, N., Deng, J., Chadashvili, T., Zhang, Y., Guo, Y., Zhang, Z. L., Yang, G. Y., Omary, R. A. & Larson, A. C. Carbogen Gas-Challenge BOLD MR Imaging in a Rat Model of Diethylnitrosamine-induced Liver Fibrosis. *Radiology* 254, 129-137 (2010).
- 26 Howe, F. A., Robinson, S. P., McIntyre, D. J. O., Stubbs, M. & Griffiths, J. R. Issues in flow and oxygenation dependent contrast (FLOOD) imaging of tumours. *Nmr in Biomedicine* 14, 497-506 (2001).
- 660 27 Kuhl, C. The current status of breast MR imaging - Part I. Choice of technique, image interpretation, diagnostic accuracy, and transfer to clinical practice. *Radiology* 244, 356-378 (2007).
- 28 El Khouli, R. H., Jacobs, M. A. & Bluemke, D. A. Magnetic resonance imaging of the breast. *Seminars in Roentgenology* 43, 265-281 (2008).
- 29 Fass, L. Imaging and cancer: A review. *Molecular Oncology* 2, 115-152 (2008).
- 30 Hirose, M., Hashizume, T., Seino, N., Kubota, H., Nobusawa, H. & Gokan, T. Atlas of breast magnetic resonance imaging. *Curr Probl Diagn Radiol* 36, 51-65 (2007).
- 31 Warren, R., Ciatto, S., Macaskill, P., Black, R. & Houssami, N. Technical aspects of breast MRI-do they affect outcomes? *European Radiology* 19, 1629-1638 (2009).
- 32 Kuhl, C. K., Schrading, S., Bieling, H. B., Wardelmann, E., Leutner, C. C., Koenig, R., Kuhn, W. & Schild, H. H. MRI for diagnosis of pure ductal carcinoma in situ: a prospective observational study. *Lancet* 370, 485-492 (2007).
- 670 33 Choe, R., Konecky, S. D., Corlu, A., Lee, K., Durduran, T., Busch, D. R., Pathak, S., Czerniecki, B. J., Tchou, J., Fraker, D. L., DeMichele, A., Chance, B., Arridge, S. R., Schweiger, M., Culver, J. P., Schnall, M. D., Putt, M. E., Rosen, M. A. & Yodh, A. G. Differentiation of benign and malignant breast tumors by in-vivo three-dimensional parallel-plate diffuse optical tomography. *J. Biomed. Opt.* 14 (2009).
- 34 Hunt, C. H., Hartman, R. P. & Hesley, G. K. Frequency and severity of adverse effects of iodinated and gadolinium contrast materials: retrospective review of 456,930 doses. *AJR Am J Roentgenol* 193, 1124-1127 (2009).



- 35 Goto, M., Ito, H., Akazawa, K., Kubota, T., Kizu, O., Yamada, K. & Nishimura, T. Diagnosis of breast tumors by contrast-enhanced MR imaging: Comparison between the diagnostic performance of dynamic enhancement patterns and morphologic features. *Journal of Magnetic Resonance Imaging* 25, 104-112 (2007).
- 680 36 Pinker, K., Grabner, G., Bogner, W., Gruber, S., Szomolanyi, P., Trattinig, S., Heinz-Peer, G., Weber, M., Fitzal, F., Pluschnig, U., Rudas, M. & Helbich, T. A Combined High Temporal and High Spatial Resolution 3 Tesla MR Imaging Protocol for the Assessment of Breast Lesions Initial Results. *Investigative Radiology* 44, 553-558 (2009).
- 37 Onesti, J. K., Mangus, B. E., Helmer, S. D. & Osland, J. S. Breast cancer tumor size: correlation between magnetic resonance imaging and pathology measurements. *American Journal of Surgery* 196, 844-848 (2008).
- 38 Silverstein, M. J., Recht, A., Lagios, M. D., Bleiweiss, I. J., Blumencranz, P. W., Gizienski, T., Harms, S. E., Harness, J., Jackman, R. J., Klimberg, V. S., Kuske, R., Levine, G. M., Linver, M. N., Rafferty, E. A., Rugo, H., Schilling, K., Tripathy, D., Whitworth, P. W. & Willey, S. C. Image-Detected Breast Cancer: State-of-the-Art Diagnosis and Treatment. *Journal of the American College of Surgeons* 209, 504-520 (2009).
- 39 Kuhl, C. K. MRI of breast tumors. *Eur Radiol* 10, 46-58 (2000).
- 690 40 Weind, K. L., Maier, C. F., Rutt, B. K. & Moussa, M. Invasive carcinomas and fibroadenomas of the breast: comparison of microvessel distributions--implications for imaging modalities. *Radiology* 208, 477-483 (1998).
- 41 Padhani, A. R. Dynamic contrast-enhanced MRI in clinical oncology: current status and future directions. *J Magn Reson Imaging* 16, 407-422 (2002).
- 42 Lewin, J. M. & Niklason, L. Advanced applications of digital mammography: tomosynthesis and contrast-enhanced digital mammography. *Semin Roentgenol* 42, 243-252 (2007).
- 43 Lewin, J. M., Isaacs, P. K., Vance, V. & Larke, F. J. Dual-energy contrast-enhanced digital subtraction mammography: feasibility. *Radiology* 229, 261-268 (2003).
- 44 Jong, R. A., Yaffe, M. J., Skarpathiotakis, M., Shumak, R. S., Danjoux, N. M., Gunsekara, A. & Plewes, D. B. Contrast-enhanced digital mammography: initial clinical experience. *Radiology* 228, 842-850 (2003).
- 700 45 Ackerman, L. V., Watt, A. C., Shetty, P., Flynn, M. J., Burke, M., Kambouris, A., Fine, G. & Wilderman, S. Breast lesions examined by digital angiography. Work in progress. *Radiology* 155, 65-68 (1985).
- 46 Watt, A. C., Ackerman, L. V., Windham, J. P., Shetty, P. C., Burke, M. W., Flynn, M. J., Grodinsky, C., Fine, G. & Wilderman, S. J. Breast lesions: differential diagnosis using digital subtraction angiography. *Radiology* 159, 39-42 (1986).
- 47 Chen, S. C., Carton, A. K., Albert, M., Conant, E. F., Schnall, M. D. & Maidment, A. D. Initial clinical experience with contrast-enhanced digital breast tomosynthesis. *Acad Radiol* 14, 229-238 (2007).
- 48 Skarpathiotakis, M., Yaffe, M. J., Bloomquist, A. K., Rico, D., Muller, S., Rick, A. & Jeunehomme, F. Development of contrast digital mammography. *Med Phys* 29, 2419-2426 (2002).
- 49 Diekmann, F. & Bick, U. Tomosynthesis and contrast-enhanced digital mammography: recent advances in digital mammography. *Eur Radiol* 17, 3086-3092 (2007).
- 710 50 Dromain, C., Balleyguier, C., Adler, G., Garbay, J. R. & Delalogue, S. Contrast-enhanced digital mammography. *Eur J Radiol* 69, 34-42 (2009).

- 51 Diekmann, F., Meyer, H., Diekmann, S., Puong, S., Muller, S., Bick, U. & Rogalla, P. Thick slices from tomosynthesis data sets: phantom study for the evaluation of different algorithms. *J Digit Imaging* 22, 519-526 (2009).
- 52 Chen, L. D., Xu, H. X., Xie, X. Y., Lu, M. D., Xu, Z. F., Liu, G. J., Liang, J. Y. & Lin, M. X. Enhancement patterns of intrahepatic cholangiocarcinoma: comparison between contrast-enhanced ultrasound and contrast-enhanced CT. *Brit J Radiol* 81, 881-889 (2008).
- 720 53 Forsberg, F., Kuruvilla, B., Pascua, M. B., Chaudhari, M. H., Merton, D. A., Palazzo, J. P. & Goldberg, B. B. Comparing contrast-enhanced color flow imaging and pathological measures of breast lesion vascularity. *Ultrasound Med Biol* 34, 1365-1372 (2008).
- 54 Zhao, H., Xu, R., Ouyang, Q., Chen, L., Dong, B. & Huihua, Y. Contrast-enhanced ultrasound is helpful in the differentiation of malignant and benign breast lesions. *Eur J Radiol* 73, 288-293 (2010).
- 55 Kettenbach, J., Helbich, T. H., Huber, S., Zuna, I. & Dock, W. Computer-assisted quantitative assessment of power Doppler US: effects of microbubble contrast agent in the differentiation of breast tumors. *Eur J Radiol* 53, 238-244 (2005).
- 56 Schroeder, R. J., Bostanjoglo, M., Rademaker, J., Maeurer, J. & Felix, R. Role of power Doppler techniques and ultrasound contrast enhancement in the differential diagnosis of focal breast lesions. *Eur Radiol* 13, 68-79 (2003).
- 57 Rubin, J. M., Bude, R. O., Carson, P. L., Bree, R. L. & Adler, R. S. Power Doppler US: a potentially useful alternative to mean frequency-based color Doppler US. *Radiology* 190, 853-856 (1994).
- 730 58 Liu, H., Jiang, Y. X., Liu, J. B., Zhu, Q. L. & Sun, Q. Evaluation of breast lesions with contrast-enhanced ultrasound using the microvascular imaging technique: Initial observations. *Breast* 17, 532-539 (2008).
- 59 Ferrara, K. W., Merritt, C. R., Burns, P. N., Foster, F. S., Mattrey, R. F. & Wickline, S. A. Evaluation of tumor angiogenesis with US: imaging, Doppler, and contrast agents. *Acad Radiol* 7, 824-839 (2000).
- 60 Balleyguier, C., Opolon, P., Mathieu, M. C., Athanasiou, A., Garbay, J. R., Delaloge, S. & Dromain, C. New potential and applications of contrast-enhanced ultrasound of the breast: Own investigations and review of the literature. *Eur. J. Radiol.* 69, 14-23 (2009).
- 61 Wright, I. A., Pugh, N. D., Lyons, K., Webster, D. J. & Mansel, R. E. Power Doppler in breast tumours: a comparison with conventional colour Doppler imaging. *Eur J Ultrasound* 7, 175-181 (1998).
- 62 Sehgal, C. M., Weinstein, S. P., Arger, P. H. & Conant, E. F. A review of breast ultrasound. *J Mammary Gland Biol Neoplasia* 11, 113-123 (2006).
- 740 63 Weskott, H. P. Emerging roles for contrast-enhanced ultrasound. *Clin Hemorheol Micro* 40, 51-71 (2008).
- 64 Cassano, E., Rizzo, S., Bozzini, A., Menna, S. & bellomi, M. Contrast enhanced ultrasound of breast cancer. *Cancer imaging* 6, 4-6 (2005).
- 65 Leff, D. R., Warren, O. J., Enfield, L. C., Gibson, A., Athanasiou, T., Patten, D. K., Hebden, J., Yang, G. Z. & Darzi, A. Diffuse optical imaging of the healthy and diseased breast: A systematic review. *Breast Cancer Research and Treatment* 108, 9-22 (2008).
- 66 Rinneberg, H., Grosenick, D., Moesta, K. T., Wabnitz, H., Mucke, J., Wubbeler, G., Macdonald, R. & Schlag, P. Detection and characterization of breast tumours by time-domain scanning optical mammography. *Opto-Electron Rev* 16, 147-162 (2008).

- 750 67 Yu, Y., Liu, N., Sassaroli, A. & Fantini, S. Near-infrared spectral imaging of the female breast for quantitative oximetry in optical mammography. *48*, D225-D235 (2009).
- 68 Fournier, L. S., Vanel, D., Athanasiou, A., Gatzemeier, W., Masuykov, I. V., Padhani, A. R., Dromain, C., Galetti, K., Sigal, R., Costa, A. & Balleyguier, C. Dynamic optical breast imaging: A novel technique to detect and characterize tumor vessels. *Eur. J. Radiol.* *69*, 43-49 (2009).
- 69 van de Ven, S., Elias, S. G., Wiethoff, A. J., van der Voort, M., Nielsen, T., Brendel, B., Bontus, C., Uhlemann, F., Nachabe, R., Harbers, R., van Beek, M., Bakker, L., van der Mark, M. B., Luijten, P. & Mali, W. Diffuse optical tomography of the breast: preliminary findings of a new prototype and comparison with magnetic resonance imaging. *European Radiology* *19*, 1108-1113 (2009).
- 70 Gibson, A. P., Hebden, J. C. & Arridge, S. R. Recent advances in diffuse optical imaging. *Phys Med Biol* *50*, R1-43 (2005).
- 760 71 Colak, S. B., van der Mark, M. B., Hooft, G. W., Hoogenraad, J. H., van der Linden, E. S. & Kuijpers, F. A. Clinical optical tomography and NIR spectroscopy for breast cancer detection. *Ieee J Sel Top Quant* *5*, 1143-1158 (1999).
- 72 Taroni, P., Pifferi, A., Salvagnini, E., Spinelli, L., Torricelli, A. & Cubeddu, R. Seven-wavelength time-resolved optical mammography extending beyond 1000 nm for breast collagen quantification. *Opt Express* *17*, 15932-15946 (2009).
- 73 Wang, J., Pogue, B. W., Jiang, S. & Paulsen, K. D. Near-infrared tomography of breast cancer hemoglobin, water, lipid, and scattering using combined frequency domain and cw measurement. *Opt Lett* *35*, 82-84 (2010).
- 74 Gibson, A. & Dehghani, H. Diffuse optical imaging. *Philosophical Transactions of the Royal Society a-Mathematical Physical and Engineering Sciences* *367*, 3055-3072 (2009).
- 75 Enfield, L. C., Gibson, A. P., Everdell, N. L., Delpy, D. T., Schweiger, M., Arridge, S. R., Richardson, C., Keshtgar, M., Douek, M. & Hebden, J. C. Three-dimensional time-resolved optical mammography of the uncompressed breast. *Appl. Optics* *46*, 3628-3638 (2007).
- 770 76 Tromberg, B. J., Pogue, B. W., Paulsen, K. D., Yodh, A. G., Boas, D. A. & Cerussi, A. E. Assessing the future of diffuse optical imaging technologies for breast cancer management. *Medical Physics* *35*, 2443-2451 (2008).
- 77 Poellinger, A., Martin, J. C., Ponder, S. L., Freund, T., Hamm, B., Bick, U. & Diekmann, F. Near-infrared Laser Computed Tomography of the Breast: First Clinical Experience. *Academic Radiology* *15*, 1545-1553 (2008).
- 78 Pogue, B. W., Jiang, S. D., Dehghani, H., Kogel, C., Soho, S., Srinivasan, S., Song, X. M., Tosteson, T. D., Poplack, S. P. & Paulsen, K. D. Characterization of hemoglobin, water, and NIR scattering in breast tissue: Analysis of intersubject variability and menstrual cycle changes. *J. Biomed. Opt.* *9*, 541-552 (2004).
- 79 Wang, B., Pivoski, S. P., Cao, X. H., Sun, D. X. & Xu, R. X. Dynamic schema for near infrared detection of pressure-induced changes in solid tumors. *Appl. Optics* *47*, 3053-3063 (2008).
- 780 80 Xu, R. X., Young, D. C., Mao, J. J. & Pivoski, S. P. A prospective pilot clinical trial evaluating the utility of a dynamic near-infrared imaging device for characterizing suspicious breast lesions. *Breast Cancer Research* *9* (2007).
- 81 Carp, S. A., Selb, J., Fang, Q., Moore, R., Kopans, D. B., Rafferty, E. & Boas, D. A. Dynamic functional and mechanical response of breast tissue to compression. *Optics Express* *16*, 16064-16078 (2008).
- 82 Intes, X., Ripoll, J., Chen, Y., Nioka, S., Yodh, A. G. & Chance, B. In vivo continuous-wave optical breast imaging enhanced with Indocyanine Green. *Med Phys* *30*, 1039-1047 (2003).

- 83 van de Ven, S., Wiethoff, A., Nielsen, T., Brendel, B., van der Voort, M., Nachabe, R., Van der Mark, M., Van Beek, M., Bakker, L., Fels, L., Elias, S., Luijten, P. & Mali, W. A novel fluorescent imaging agent for diffuse optical tomography of the breast: first clinical experience in patients. *Mol Imaging Biol* 12, 343-348 (2010).
- 84 Xu, M. H. & Wang, L. H. V. Photoacoustic imaging in biomedicine. *Review of Scientific Instruments* 77 (2006).
- 790 85 Wang, L. V. Multiscale photoacoustic microscopy and computed tomography. *Nature Photonics* 3, 503-509 (2009).
- 86 Lao, Y. Q., Xing, D., Yang, S. H. & Xiang, L. Z. Noninvasive photoacoustic imaging of the developing vasculature during early tumor growth. *Physics in Medicine and Biology* 53, 4203-4212 (2008).
- 87 Li, V. & Wang, L. H. V. Photoacoustic tomography and sensing in biomedicine. *Physics in Medicine and Biology* 54, R59-R97 (2009).
- 88 Manohar, S., Kharine, A., van Hespren, J. C. G., Steenbergen, W. & van Leeuwen, T. G. Photoacoustic mammography laboratory prototype: imaging of breast tissue phantoms. *Journal of Biomedical Optics* 9, 1172-1181 (2004).
- 89 Oraevsky, A. A. & Wang, L. H. V. *Photoacoustic Imaging and Spectroscopy (Chapter 33)*. 1 edn, 411-429 (CRC Press Taylor&Francis Group, 2009).
- 90 Jose, J., Manohar, S., Kolkman, R. G. M., Steenbergen, W. & van Leeuwen, T. G. Imaging of tumor vasculature using Twente photoacoustic systems. *J Biophotonics* 2, 701-717 (2009).
- 800 91 Kolkman, R. G. M., Brands, P. J., Steenbergen, W. & van Leeuwen, T. G. Real-time in vivo photoacoustic and ultrasound imaging. *J. Biomed. Opt.* 13, - (2008).
- 92 Erpelding, T. N., Kim, C., Pramanik, M., Jankovic, L., Maslov, K., Guo, Z., Margenthaler, J. A., Pashley, M. D. & Wang, L. V. Sentinel lymph nodes in the rat: noninvasive photoacoustic and US imaging with a clinical US system. *Radiology* 256, 102-110 (2010).
- 93 Laufer, J. G., Elwell, C. E., Delpy, D. T. & Beard, C. C. Spatially resolved blood oxygenation measurements using time-resolved photoacoustic spectroscopy. *Adv Exp Med Biol* 578, 155-160 (2006).
- 94 Zhang, H. F., Maslov, K., Sivaramkrishnan, M., Stoica, G. & Wang, L. H. V. Imaging of hemoglobin oxygen saturation variations in single vessels in vivo using photoacoustic microscopy. *Appl Phys Lett* 90, - (2007).
- 810 95 Yao, J., Maslov, K., Hu, S. & Wang, L. V. Evans blue dye-enhanced capillary-resolution photoacoustic microscopy in vivo. *J Biomed Opt* 14, 054049 (2009).
- 96 Eghtedari, M., Oraevsky, A., Copland, J. A., Kotov, N. A., Conjusteau, A. & Motamedi, M. High sensitivity of in vivo detection of gold nanorods using a laser photoacoustic imaging system. *Nano Lett* 7, 1914-1918 (2007).
- 97 Taruttis, A., Herzog, E., Razansky, D. & Ntziachristos, V. Real-time imaging of cardiovascular dynamics and circulating gold nanorods with multispectral photoacoustic tomography. *Optics Express* 18, 19592-19602 (2010).
- 98 Pan, D., Pramanik, M., Senpan, A., Allen, J. S., Zhang, H., Wickline, S. A., Wang, L. V. & Lanza, G. M. Molecular photoacoustic imaging of angiogenesis with integrin-targeted gold nanobeacons. *FASEB J* 25, 875-882 (2011).
- 99 De La Zerda, A., Zavaleta, C., Keren, S., Vaithilingam, S., Bodapati, S., Liu, Z., Levi, J., Smith, B. R., Ma, T. J., Oralkan, O., Cheng, Z., Chen, X. Y., Dai, H. J., Khuri-Yakub, B. T. & Gambhir, S. S. Carbon nanotubes as photoacoustic molecular imaging agents in living mice. *Nat Nanotechnol* 3, 557-562 (2008).
- 820 100 Telenkov, S. A. & Mandelis, A. Photothermal photoacoustic imaging of biological tissues: maximum depth characterization comparison of time and frequency-domain measurements. *J Biomed Opt* 14, 044025 (2009).

- 101 Wang, L. V. Tutorial on photoacoustic microscopy and computed tomography. *Ieee Journal of Selected Topics in Quantum Electronics* 14, 171-179 (2008).
- 102 Ermilov, S. A., Khamapirad, T., Conjusteau, A., Leonard, M. H., Lacewell, R., Mehta, K., Miller, T. & Oraevsky, A. A. Laser photoacoustic imaging system for detection of breast cancer. *Journal of Biomedical Optics* 14 (2009).
- 103 Khokhlova, T. D., Pelivanov, I. M., Kozhushko, V. V., Zharinov, A. N., Solomatin, V. S. & Karabutov, A. A. Photoacoustic imaging of absorbing objects in a turbid medium: ultimate sensitivity and application to breast cancer diagnostics. *Applied Optics* 46, 262-272 (2007).
- 830 104 Manohar, S., Kharine, A., van Hespren, J. C. G., Steenbergen, W. & van Leeuwen, T. G. The Twente Photoacoustic Mammoscope: system overview and performance. *Physics in Medicine and Biology* 50, 2543-2557 (2005).
- 105 Pramanik, M., Ku, G., Li, C. H. & Wang, L. V. Design and evaluation of a novel breast cancer detection system combining both thermoacoustic (TA) and photoacoustic (PA) tomography. *Medical Physics* 35, 2218-2223 (2008).
- 106 Jose, J., Manohar, S., Kolkman, R. G., Steenbergen, W. & van Leeuwen, T. G. Imaging of tumor vasculature using Twente photoacoustic systems. *J Biophotonics* 2, 701-717 (2009).
- 107 Manohar, S., Vaartjes, S. E., van Hespren, J. C. G., Klaase, J. M., van den Engh, F. M., Steenbergen, W. & van Leeuwen, T. G. Initial results of in vivo non-invasive cancer imaging in the human breast using near-infrared photoacoustics. *Optics Express* 15, 12277-12285 (2007).
- 108 Manohar, S. & Wang, L. H. V. *Photoacoustic Imaging and Spectroscopy (Chapter 34)*. 1 edn, 431-441 (CRC Press Taylor&Francis Group, 2009).
- 840 109 Piras, D., Xia, W. F., Steenbergen, W., van Leeuwen, T. G. & Manohar, S. Photoacoustic Imaging of the Breast Using the Twente Photoacoustic Mammoscope: Present Status and Future Perspectives. *Ieee J Sel Top Quant* 16, 730-739 (2010).
- 110 Sorelli, P. G., Cosgrove, D. O., Svensson, W. E., Zaman, N., Satchithananda, K., Barrett, N. K. & Lim, A. K. P. Can Contrast-Enhanced Sonography Distinguish Benign From Malignant Breast Masses? *Journal of Clinical Ultrasound* 38, 177-181 (2010).
- 111 Banks, E., Reeves, G., Beral, V., Bull, D., Crossley, B., Simmonds, M., Hilton, E., Bailey, S., Barrett, N., Briers, P., English, R., Jackson, A., Kutt, E., Lavelle, J., Rockall, L., Wallis, M. G., Wilson, M. & Patnick, J. Influence of personal characteristics of individual women on sensitivity and specificity of mammography in the Million Women Study: cohort study. *BMJ* 329, 477 (2004).
- 850 112 Jensen, A., Geller, B. M., Gard, C. C., Miglioretti, D. L., Yankaskas, B., Carney, P. A., Rosenberg, R. D., Vejborg, I. & Lynge, E. Performance of diagnostic mammography differs in the United States and Denmark. *Int J Cancer* 127, 1905-1912 (2010).
- 113 Houssami, N., Irwig, L., Simpson, J. M., McKessar, M., Blome, S. & Noakes, J. The influence of knowledge of mammography findings on the accuracy of breast ultrasound in symptomatic women. *Breast J* 11, 167-172 (2005).
- 114 Benndorf, M., Baltzer, P. A., Vag, T., Gajda, M., Runnebaum, I. B. & Kaiser, W. A. Breast MRI as an adjunct to mammography: Does it really suffer from low specificity? A retrospective analysis stratified by mammographic BI-RADS classes. *Acta Radiol* 51, 715-721 (2010).

- 860 115 Balas, C. Review of biomedical optical imaging-a powerful, non-invasive, non-ionizing technology for improving in vivo diagnosis. *Meas. Sci. Technol.* 20 (2009).
- 116 Fracheboud, J., de Gelder, R., Otto, S. J., van Ineveld, B. M., Otten, J. D. M., Broeders, M. J. M., Verbeek, A. L. M., den Heeten, G., Holland, R., de Bruijn, A., E. & De Koning, H. J. *National evaluation of breast cancer screening in the Netherlands 1990-2007 (XII) Twelfth evaluation report.* (Landelijk Evaluatie Team voor bevolkingsonderzoek naar Borstkanker (LETB), 2009).
- 117 Houssami, N., Lord, S. J. & Ciatto, S. Breast cancer screening: emerging role of new imaging techniques as adjuncts to mammography. *Med J Aust* 190, 493-497 (2009).
- 870 118 Sardanelli, F., Boetes, C., Borisch, B., Decker, T., Federico, M., Gilbert, F. J., Helbich, T., Heywang-Kobrunner, S. H., Kaiser, W. A., Kerin, M. J., Mansel, R. E., Marotti, L., Martincich, L., Mauriac, L., Meijers-Heijboer, H., Orecchia, R., Panizza, P., Ponti, A., Purushotham, A. D., Regitnig, P., Del Turco, M. R., Thibault, F. & Wilson, R. Magnetic resonance imaging of the breast: Recommendations from the EUSOMA working group. *European Journal of Cancer* 46, 1296-1316 (2010).
- 119 Manohar, S., Willeminck, R. G. H., van der Heijden, F., Slump, C. H. & van Leeuwen, T. G. Concomitant speed-of-sound tomography in photoacoustic imaging. *Appl Phys Lett* 91, - (2007).
- 120 Bluemke, D. A., Gatsonis, C. A., Chen, M. H., DeAngelis, G. A., DeBruhl, N., Harms, S., Heywang-Kobrunner, S. H., Hylton, N., Kuhl, C. K., Lehman, C., Pisano, E. D., Causer, P., Schnitt, S. J., Smazal, S. F., Stelling, C. B., Weatherall, P. T. & Schnall, M. D. Magnetic resonance imaging of the breast prior to biopsy. *JAMA* 292, 2735-2742 (2004).
- 121 Diekmann, F., Freyer, M., Diekmann, S., Fallenberg, E. M., Fischer, T., Bick, U. & Pollinger, A. Evaluation of contrast-enhanced digital mammography. *Eur J Radiol* (2009).
- 880 122 Caproni, N., Marchisio, F., Pecchi, A., Canossi, B., Battista, R., D'Alimonte, P. & Torricelli, P. Contrast-enhanced ultrasound in the characterisation of breast masses: utility of quantitative analysis in comparison with MRI. *Eur Radiol* 20, 1384-1395 (2010).
- 123 Sardanelli, F. & Podo, F. Breast MR imaging in women at high-risk of breast cancer. Is something changing in early breast cancer detection? *European Radiology* 17, 873-887 (2007).
- 124 Kuhl, C. K., Schrading, S., Leutner, C. C., Morakkabati-Spitz, N., Wardelmann, E., Fimmers, R., Kuhn, W. & Schild, H. H. Mammography, breast ultrasound, and magnetic resonance imaging for surveillance of women at high familial risk for breast cancer. *J Clin Oncol* 23, 8469-8476 (2005).
- 890 125 Kriege, M., Brekelmans, C. T. M., Boetes, C., Besnard, P. E., Zonderland, H. M., Obdeijn, I. M., Manoliu, R. A., Kok, T., Peterse, H., Tilanus-Linthorst, M. M. A., Muller, S. H., Meijer, S., Oosterwijk, J. C., Beex, L. V. A. M., Tollenaar, R. A. E. M., de Koning, H. J., Rutgers, E. J. T., Klijn, J. G. M. & Screeni, M. R. I. Efficacy of MRI and mammography for breast-cancer screening in women with a familial or genetic predisposition. *New Engl J Med* 351, 427-437 (2004).
- 126 Kruger, R. A., Lam, R. B., Reinecke, D. R., Del Rio, S. P. & Doyle, R. P. Photoacoustic angiography of the breast. *Med Phys* 37, 6096-6100 (2010).

Figure 1 a-b

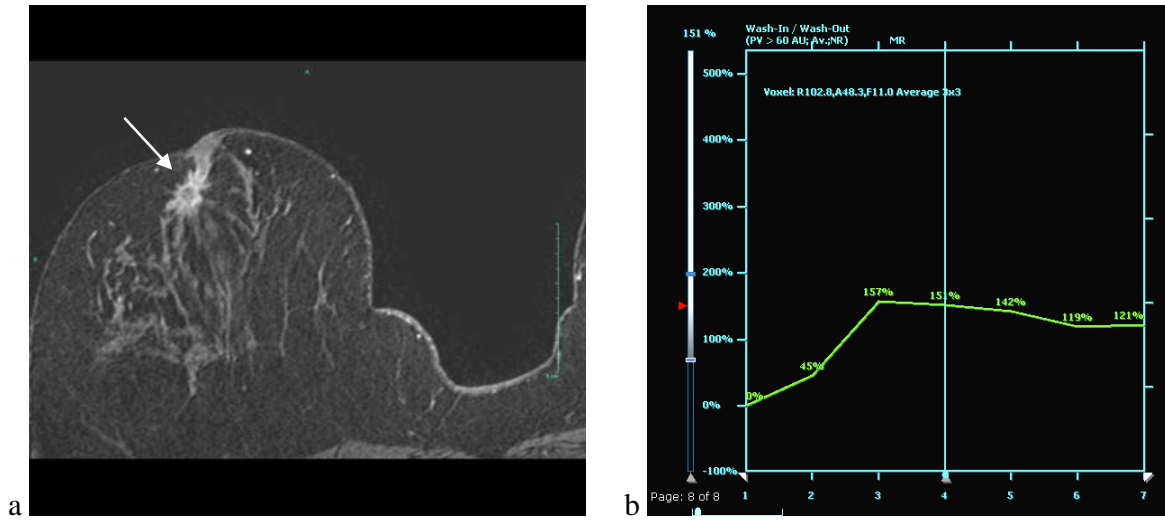
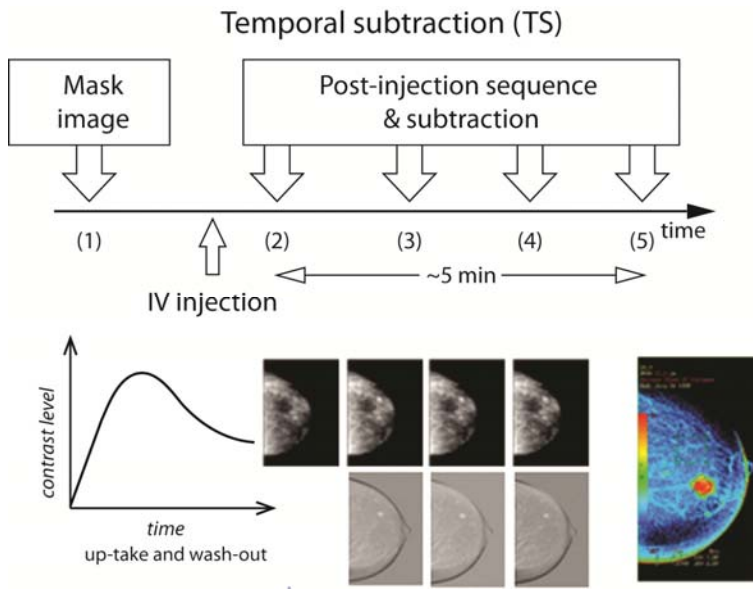


Figure 2



900

Figure 3

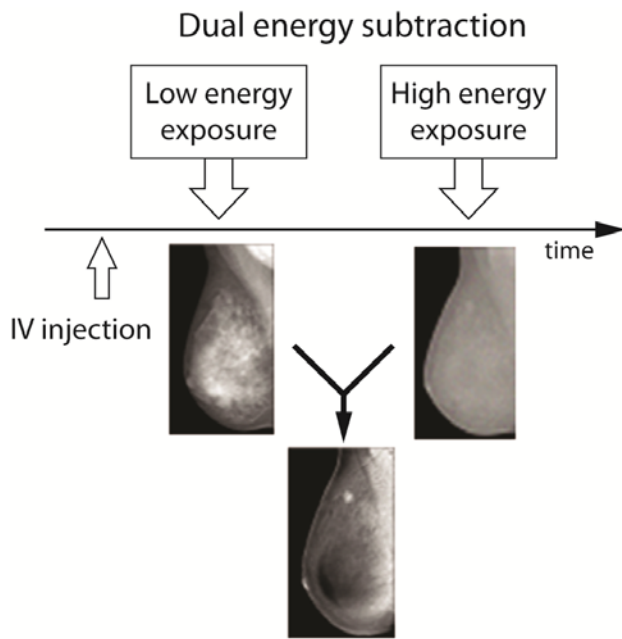


Figure 4 a-c

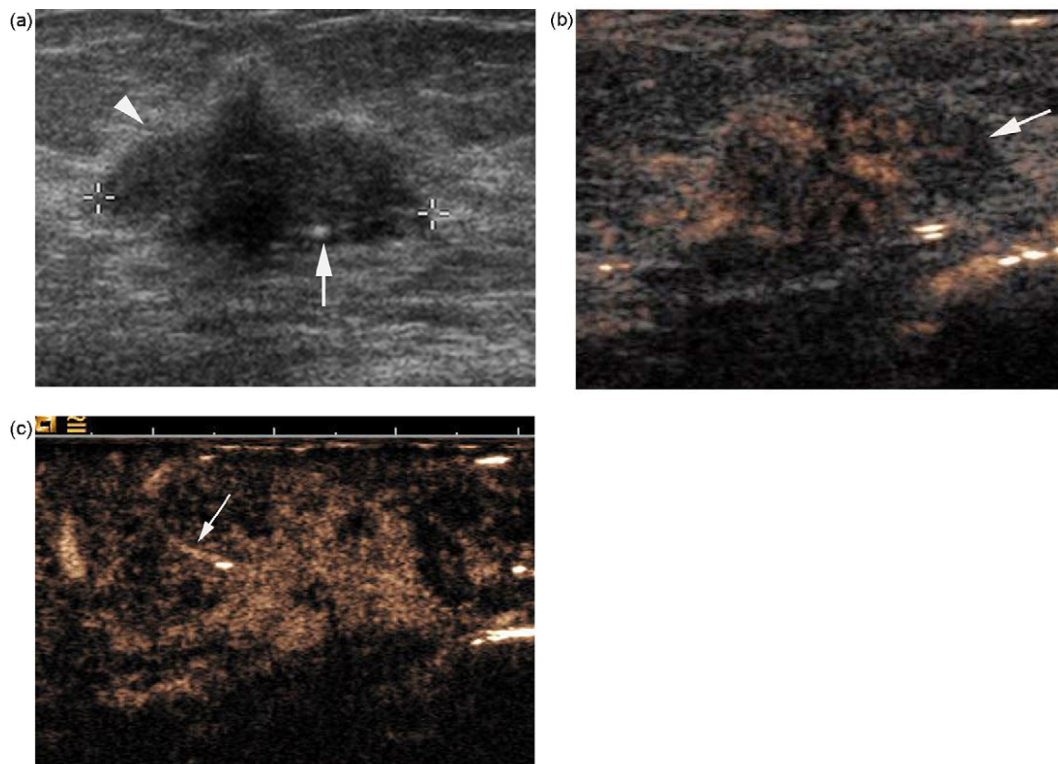
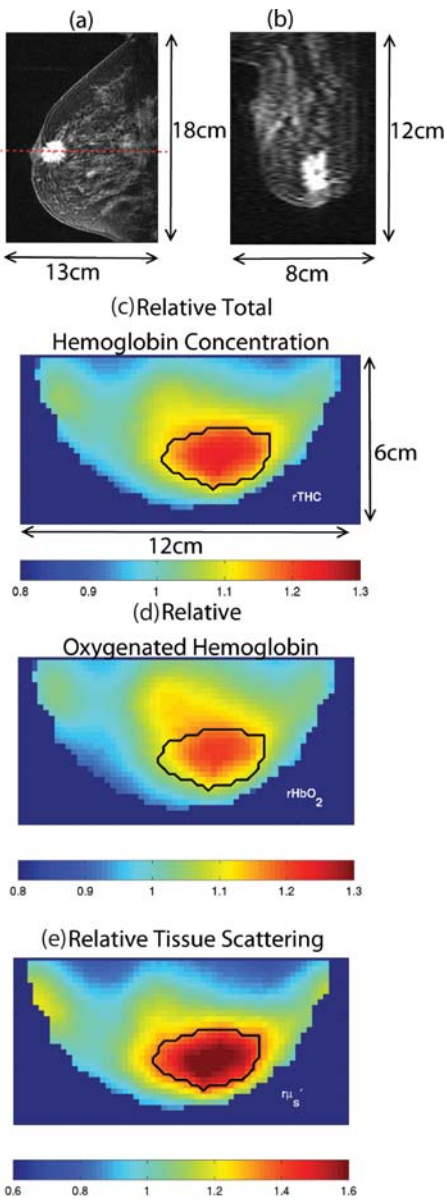




Figure 5



910

Figure 6 a-b

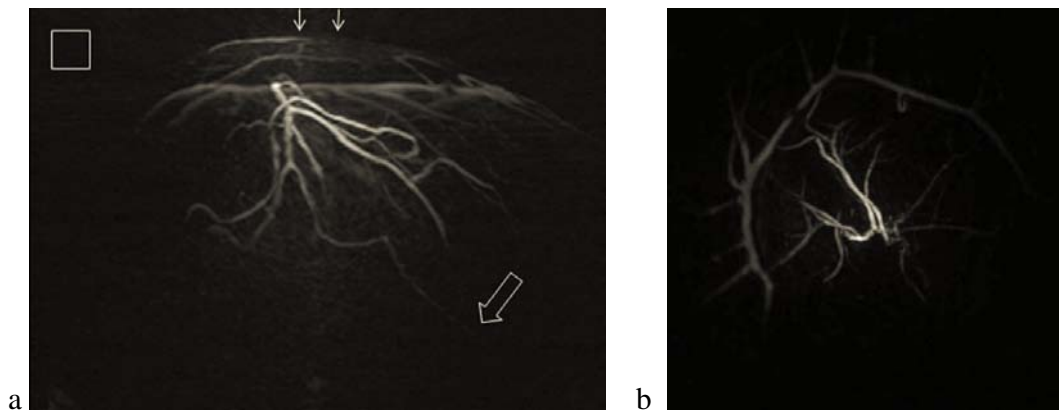


Figure 7

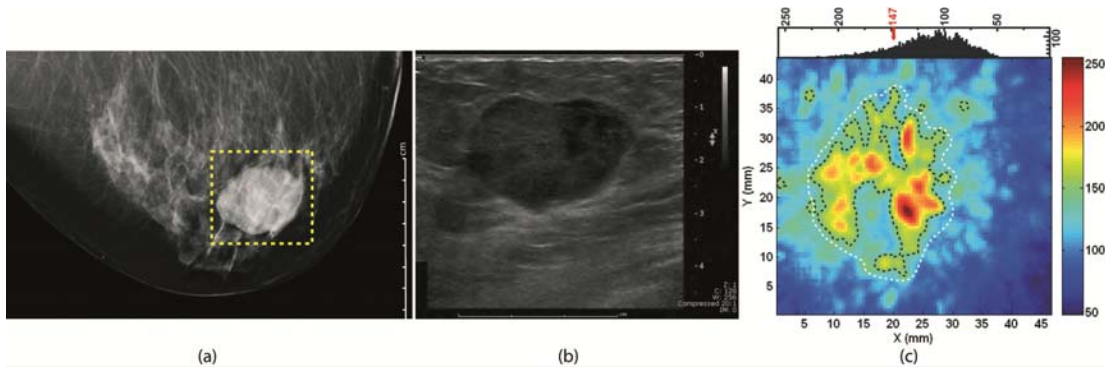


Table I

	DCE-MRI	CEDM	Doppler US	CEUS	DOI	PAI
Resolution	++	++	+	+	-	+
Contrast	++	+	-	+/-	++	++
Sensitivity	++	+/-	+/-	+	*TBD	*TBD
Specificity	-	+/-	+/-	+/-	*TBD	*TBD
Applicability	+/-	+/-	+	+	+	+
Ionizing Radiation	+	-	+	+	+	+
Contrast Agents	-	-	+	-	+	+
Assessment of MVD	+	+	+	+	+	+
Assessment of vessel characteristics	+	+	-	-	-	-
Full 3D breast scanning	+	-	-	-	+	+
Duration	-	+	+	+	-	-
Costs	-	+/-	+	+	+/-	+/-

Table II

Technique:	Study	Number of patients	Sensitivity	Specificity
<i>x-ray (digital) mammography</i>	Jensen 2010 (112)	93,585 (United States)	85.0%	93.2%
	Jensen 2010 (112)	51,313 (Denmark)	82.4%	98.6%
<i>Ultrasonography</i>	Houssami 2005 (113)	480 (without x-ray knowledge)	79.4%	88.4%
	Houssami 2005 (113)	480 (with x-ray knowledge)	87.1%	85.2%
<i>Dynamic Contrast Enhanced Magnetic Resonance Imaging</i>	Bluemke 2004 (120)	821 (BIRADS 4-5)	88.1%	67.7%
<i>Contrast Enhanced Digital Mammography</i>	Dromain 2006 (50)	20	80%	*
	Diekmann 2009 (121)	80 (suspicious lesions on MMG/US or MRI)	62%	70%
<i>Contrast Enhanced Ultrasound</i>	Caproni 2010 (122)	39 (BIRADS 3-5 at MMG or US)	91%	73%
	Sorelli 2010 (110)	15	100%	37.5%
	Zhao 2010 (54)	71 (combined with US)	86.6%	96.8%
	Liu 2008(58)	104	95.3%	88.3%

Table III

Technique:	Study	Number of patients	Sensitivity	Specificity
<i>x-ray(digital) mammography</i>	Sardanelli 2007 (123)	3,571	39.5%	*
	Kuhl 2005 (124)	529	32.6%	96.8%
	Kriege 2004 (125)	1,909	40%	95%
<i>Ultrasonography</i>	Sardanelli 2007 (123)	3,571	43.2%	*
	Kuhl 2005 (124)	529	39.5%	90.5%
<i>Dynamic Contrast Enhanced Magnetic Resonance Imaging</i>	Sardanelli 2007 (123)	3,571	80.7%	*
	Kuhl 2005 (124)	529	90.7%	97.2%
	Kriege 2004 (125)	1,909	71%	89.8%

**Figure 1** Example of a Dynamic Contrast Enhanced MRI image. **a)** T1 weighted image after gadolinium injection. This image shows a region with contrast enhancement (arrow) close to the nipple of the patient's right breast. The area is suggestive for the presence of an infiltrating malignancy. **b)** Dynamic contrast enhancement curve. This figure shows the percentage contrast enhancement (vertical axis) in the suspicious area as a function of time (horizontal axis, in minutes after contrast injection). The rapid wash-in (to 151% at four minutes) and a 20% wash-out (to 121% at seven minutes) of contrast in this region are suggestive for the presence of malignancy.

930 **Figure 2** The principle of temporal subtraction contrast enhanced digital mammography (CEDM). High energy images are obtained before and at various time points after the injection of contrast medium. Afterwards, the pre-contrast image is subtracted from the post-contrast images. Reprinted and adapted with permission from (50).

**Figure 3** The principle of dual energy subtraction contrast enhanced digital mammography (CEDM). Images are obtained by using energies both below and above the k-edge of iodine. The subtraction of the two images shows the iodine enhancement. Figure reprinted and adapted with permission from (50).

940 **Figure 4:** Contrast US before and after contrast medium injection. 23mm ductal infiltrative carcinoma. **a)** B mode sonography. Spiculated mass, classified as highly suspicious for malignancy. Infiltrative feature is suspected because of the echogenicity of the surrounding fat (arrowhead). Microcalcifications are also visible within the tumor (arrow). **b)** Same patient. Contrast US including B mode and contrast mode (SonoVue®). The tumor is strongly enhanced after injection. Vessels are located in the peripheral area of the lesion. An area of the lesion remains poorly enhanced (arrow) which corresponds to necrosis. **c)** Same patient. Contrast US with CPS®, contrast mode only. Figure reprinted with permission from (60). PERMISSION AND ORIGINAL HIGH-RESOLUTION FIGURES ARE AWAITED.

950 **Figure 5** Breast MRI and frequency domain DOI of a 53 year old women with a 2.2 cm infiltrating ductal carcinoma. **a)** Sagittal DCE-MRI image and **b)** axial DCE-MRI image. The gadolinium contrast enhancement visualizes the malignancy. **c-e)** DOI images obtained from multispectral analysis of frequency domain data (33) representing relative total hemoglobin concentration, relative oxygenated hemoglobin and relative tissue scattering. The higher contrast in the indicated areas in Figure c, d and e, indicates that, amongst others, the relative total hemoglobin concentration, the relative oxygenated hemoglobin and the relative tissue scattering can give information about the presence of a malignancy. Image reprinted with permission from (33).

**Figure 6** Maximum Intensity Projection of the photoacoustic tomography images of the breast of a 57 year old volunteer. **a)** Lateral projection and **b)** anterior-posterior projection. The square in Figure **a)** represents a 1x1 cm<sup>2</sup> area. In this figure, a submillimeter vessel is visible to a depth of 40 mm (hollow arrow) beneath the front of the breast (two arrows). The images are obtained by using an 800 nm pulsed laser source and 128.5 MHz ultrasound detectors positioned in a hemispherical configuration. Imaging reprinted with permission from (126).

960 **Figure 7** X-ray (a), ultrasound (b) and photoacoustic (c) images of a 50 year old woman with a palpable breast lesion. The photoacoustic image is obtained with the Twente Photoacoustic Mammoscope (PAM) in a clinical pilot study in 2006. A 1064 nm pulsed laser source is used in a transillumination approach with a planar array of 590 1 MHz ultrasound detectors. Both the x-ray and ultrasound images were highly suspicious for malignancy. The photoacoustic image also showed a region with higher signals, indicating a region with higher vascularity. The lesion was histopathologically determined as an infiltrating ductal carcinoma. Image reprinted with permission from (107).

**Table I** This Table summarizes the advantages and disadvantages per imaging technique that is described in this review. \*TBD: those properties are yet to be determined.

970 **Table II** Sensitivity and specificity for diagnostic breast imaging. The performance of the conventional imaging methods, digital x-ray mammography and ultrasonography, are compared with the performances of dynamic contrast enhanced magnetic resonance imaging, contrast enhanced digital mammography and contrast enhanced ultrasound. Different studies are reported to show the high variation in sensitivity and specificity numbers. Sensitivity and specificity numbers for DOI and PAI are yet to be determined. \*Specificity numbers not reported.

**Table III** Sensitivity and specificity numbers for screening for breast cancer in high-risk women. The only vascularization imaging method that is applied in this context is dynamic contrast enhanced magnetic resonance imaging. Its performance is compared with that of the conventional techniques: digital x-ray mammography and ultrasonography. \*Specificity numbers not reported.

980